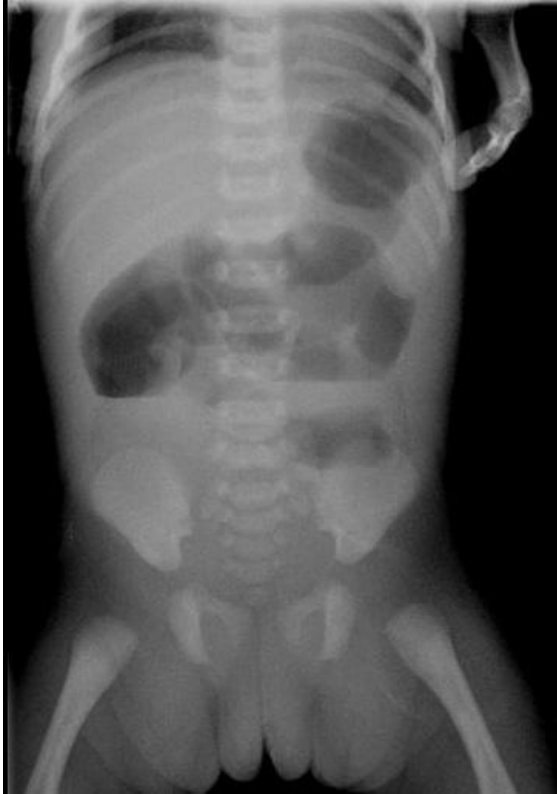

# File:Atrezie jejuna IV. typ 1. snimek.JPG



No higher resolution available.

Atrezie\_jejuna\_IV.\_typ\_1.\_snimek.JPG (361 × 516 pixels, file size: 16 KB, MIME type: image/jpeg)

## Summary

### Description

Visceral abdominal X-ray in a preterm neonate with type IV atresia of the jejunum

### Author

FNM KZM

### Source

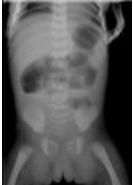
FNM KZM

### Date

2016

## File history

Click on a date/time to view the file as it appeared at that time.

	Date/Time	Thumbnail	Dimensions	User	Comment
current	<b>01:32, 18 January 2022</b>		361 × 516 (16 KB)	MartinRuzicka (talk   contribs)	{{File  description = Visceral abdominal X-ray in a preterm neonate with type IV atresia of the jejunum  author = FNM KZM  source = FNM KZM  date = 2016 }}

You cannot overwrite this file.

## File usage

The following page uses this file:

- Congenital defects of the gastrointestinal tract