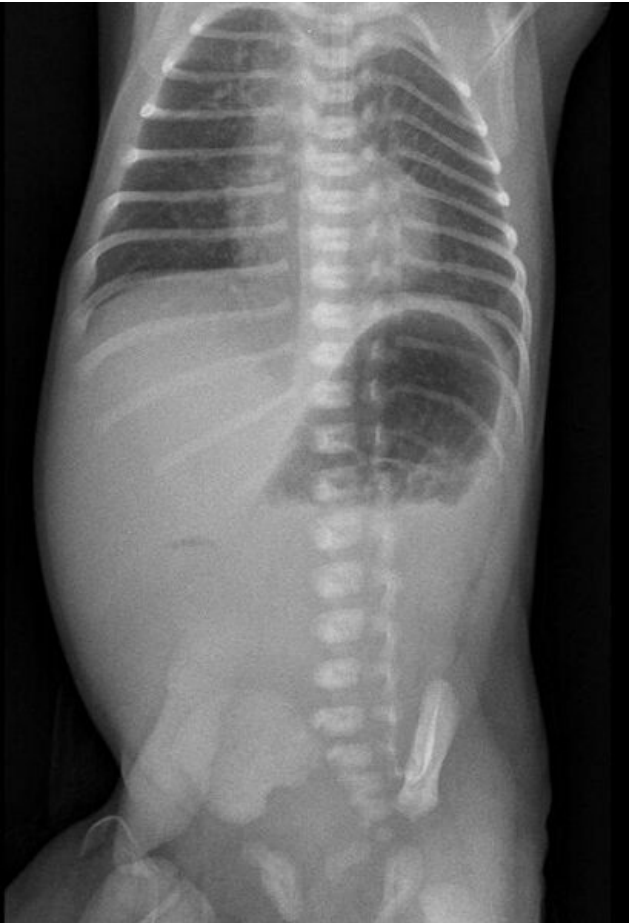


File:Atrezie duodena novorozenec.JPG



Size of this preview: 409 × 599 pixels.

Original file (482 × 706 pixels, file size: 36 KB, MIME type: image/jpeg)

 [Open in Media Viewer](#)



Summary

Description
Abdominal X-ray in a slightly premature newborn with duodenal atresia


Author
FNM KZM

Source
FNM KZM

Date
13.11.2017

File history

Click on a date/time to view the file as it appeared at that time.

	Date/Time	Thumbnail	Dimensions	User	Comment
current	01:17, 18 January 2022		482 × 706 (36 KB)	MartinRuzicka (talk contribs)	{ {File description = Abdominal X-ray in a slightly premature newborn with duodenal atresia author = FNM KZM source = FNM KZM date = 13.11.2017 } }

You cannot overwrite this file.

File usage

The following page uses this file:

- Congenital defects of the gastrointestinal tract