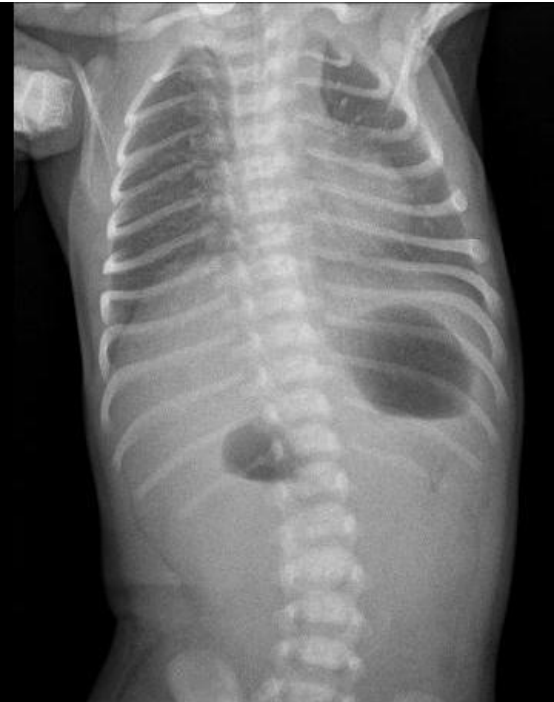

File:Atrezie duodena a pankreas annulare.JPG



No higher resolution available.

Atrezie_duodena_a_pankreas_annulare.JPG (360 × 455 pixels, file size: 18 KB, MIME type: image/jpeg)

Summary

Description
Typical "double bubble" image on abdominal X-ray in a patient with duodenal atresia and pancreas annulare


Author
FNM KZM

Source
FNM KZM

Date
2017

File history

Click on a date/time to view the file as it appeared at that time.

	Date/Time	Thumbnail	Dimensions	User	Comment
current	01:07, 18 January 2022		360 × 455 (18 KB)	MartinRuzicka (talk contribs)	{{File description = Typical "double bubble" image on abdominal X-ray in a patient with duodenal atresia and pancreas annulare author = FNM KZM source = FNM KZM date = 2017 }}

You cannot overwrite this file.

File usage

The following page uses this file:

- Congenital defects of the gastrointestinal tract