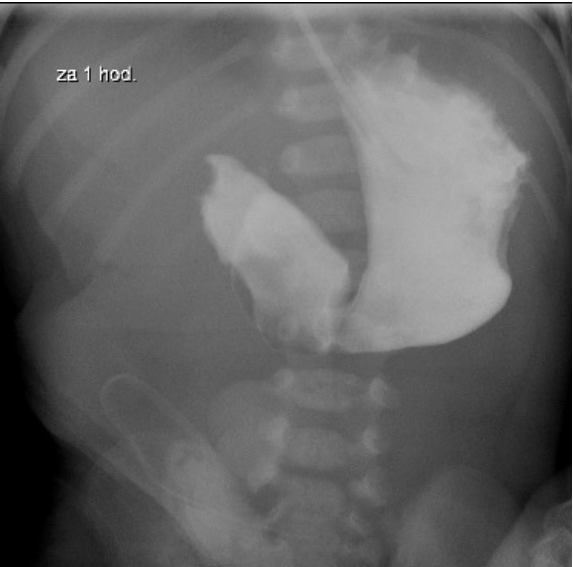


File:Atrezie duodena - kontrast pasaz.jpg



No higher resolution available.

Atrezie_duodena_-_kontrast_pasaz.jpg (372 × 367 pixels, file size: 31 KB, MIME type: image/jpeg)

Summary

Description

Radiograph taken one hour after contrast administration to the stomach to confirm the diagnosis of duodenal atresia

Author

FNM KZM

Source

FNM KZM

Date

2013

File history

Click on a date/time to view the file as it appeared at that time.

	Date/Time	Thumbnail	Dimensions	User	Comment
current	02:19, 18 January 2022		372 × 367 (31 KB)	MartinRuzicka (talk contribs)	{{File description = Radiograph taken one hour after contrast administration to the stomach to confirm the diagnosis of duodenal atresia author = FNM KZM source = FNM KZM date = 2013 }}

You cannot overwrite this file.

File usage

The following page uses this file:

- Congenital defects of the gastrointestinal tract