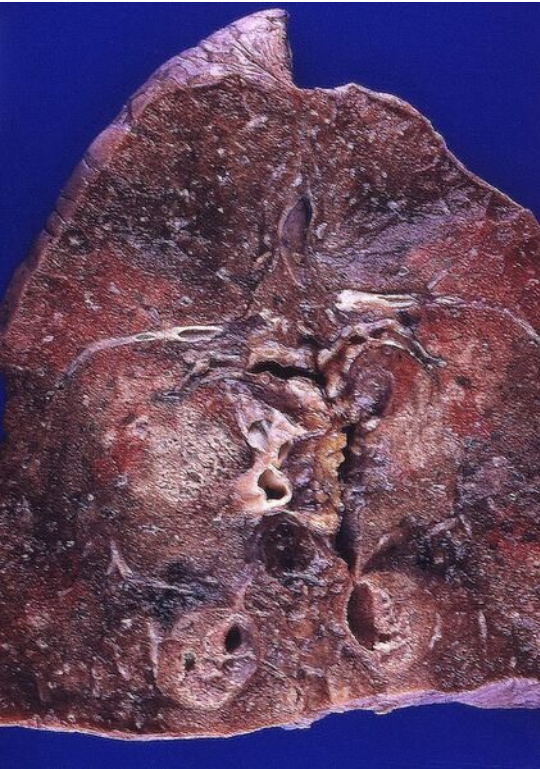

# File:Aspiration pneumonia.jpg



Size of this preview: 422 × 599 pixels.

Original file (451 × 640 pixels, file size: 316 KB, MIME type: image/jpeg)

## Summary

### Description

Aspiration pneumonia.

Finding in lung section on examination

### Author

Yale Rosen, M.D.

### Source

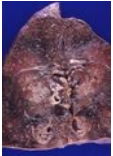
[http://www.flickr.com/photos/pulmonary\\_pathology/5613904516/sizes/z/in/set-72157620676446291/](http://www.flickr.com/photos/pulmonary_pathology/5613904516/sizes/z/in/set-72157620676446291/)

### Date

Date

## File history

Click on a date/time to view the file as it appeared at that time.

	Date/Time	Thumbnail	Dimensions	User	Comment
current	<b>23:16, 16 December 2021</b>		451 × 640 (316 KB)	Slawia (talk   contribs)	{ {File  description = Aspiration pneumonia. Finding in lung section on examination  author = Yale Rosen, M.D.  source = <a href="http://www.flickr.com/photos/pulmonary_pathology/5613904516/sizes/z/in/set-72157620676446291/">http://www.flickr.com/photos/pulmonary_pathology/5613904516/sizes/z/in/set-72157620676446291/</a>  date = Date } }

You cannot overwrite this file.

## File usage

The following page uses this file:

- Aspiration of a foreign body