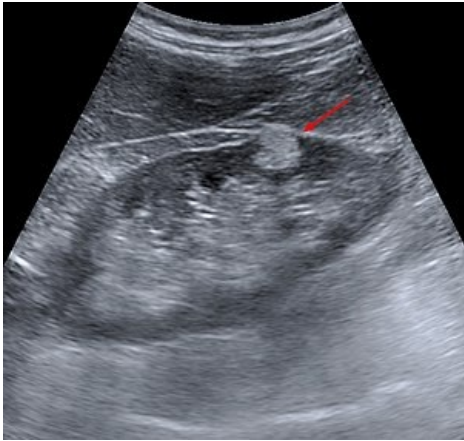


File:Angiomyolipom der Niere Sonographie.jpg



No higher resolution available.


Angiomyolipom_der_Niere_Sonographie.jpg (300 × 284 pixels, file size: 22 KB, MIME type: image/jpeg)

 **Open in Media Viewer** 

Angiomyolipoma - ultrasound - hyperechoic focus /fat/

File history

Click on a date/time to view the file as it appeared at that time.

	Date/Time	Thumbnail	Dimensions	User	Comment
current	14:39, 8 April 2023		300 × 284 (22 KB)	Sagihoz (talk contribs)	

You cannot overwrite this file.

File usage

The following 2 pages use this file:

- Benign kidney tumors
- Benign renal tumors