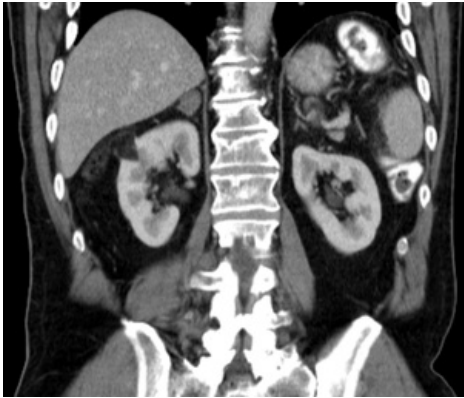

# File:Angiomyolipom Niere rechts CT coronor.png




No higher resolution available.

Angiomyolipom\_Niere\_rechts\_CT\_coronor.png (300 × 256 pixels, file size: 46 KB, MIME type: image/png)

Angiomyolipoma of the right kidney - CT - hypodense focus /fat/

## File history

Click on a date/time to view the file as it appeared at that time.

	Date/Time	Thumbnail	Dimensions	User	Comment
current	14:39, 8 April 2023		300 × 256 (46 KB)	Sagihoz (talk   contribs)	

You cannot overwrite this file.

## File usage

The following 2 pages use this file:

- Benign kidney tumors
- Benign renal tumors

## Metadata

This file contains additional information, probably added from the digital camera or scanner used to create or digitize it.

If the file has been modified from its original state, some details may not fully reflect the modified file.