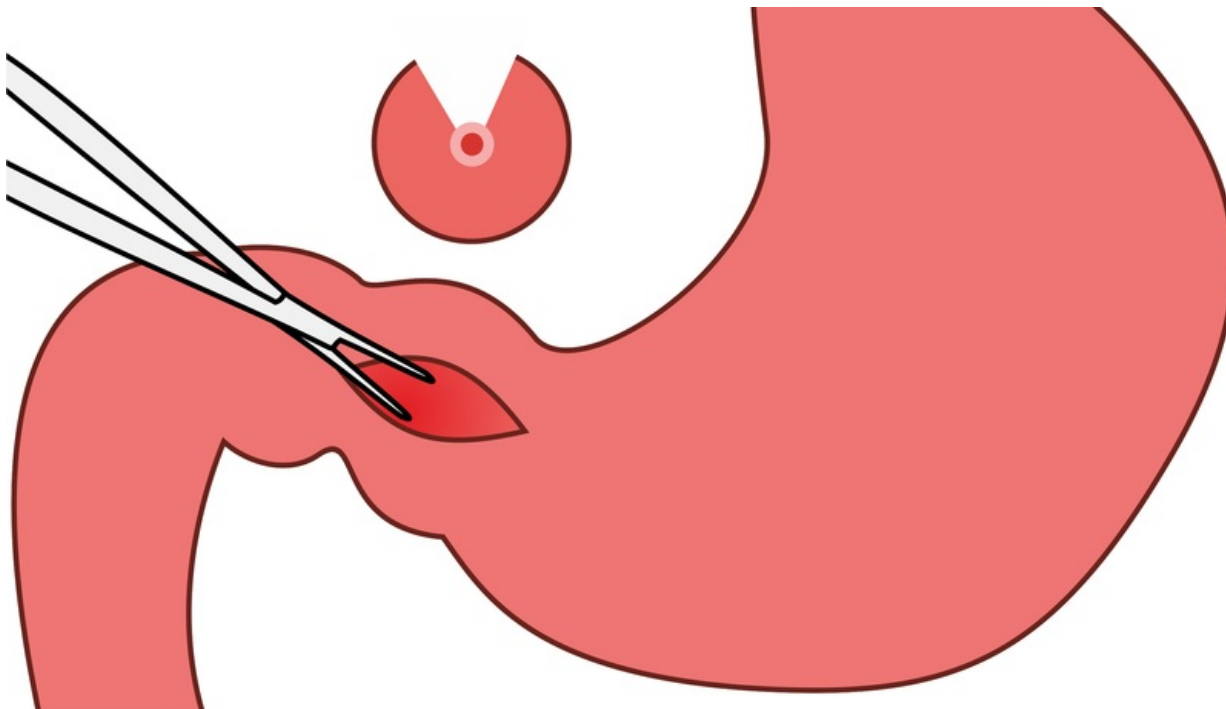


File:1600px-Pylorostenóza3.png



Size of this preview: 800 × 458 pixels.

Original file (1,600 × 915 pixels, file size: 215 KB, MIME type: image/png)

 [Open in Media Viewer](#) 

Summary

Description

Pylorostenosis - splitting of the pyloric hypertrophic musculature

Author

Adnav

Source


own work

Date

2014-04-14

File history

Click on a date/time to view the file as it appeared at that time.

	Date/Time	Thumbnail	Dimensions	User	Comment
current	01:37, 18 January 2022		1,600 × 915 (215 KB)	MartinRuzicka (talk contribs)	<div>{{File description = Pylorostenosis - splitting of the pyloric hypertrophic musculature author = Adnav source = own work date = 2014-04-14 }}</div>

You cannot overwrite this file.

File usage

The following page uses this file:

- Congenital defects of the gastrointestinal tract

Metadata

This file contains additional information, probably added from the digital camera or scanner used to create or digitize it.

If the file has been modified from its original state, some details may not fully reflect the modified file.