

# Falx inguinalis

**Falx inguinalis** (also *tendo conjunctivus*) is a structure that is formed by the fusion of the lower edges of the aponeuroses of the obliquus internus abdominis and transversus abdominis muscles. It borders the trigonum inguinale medially.

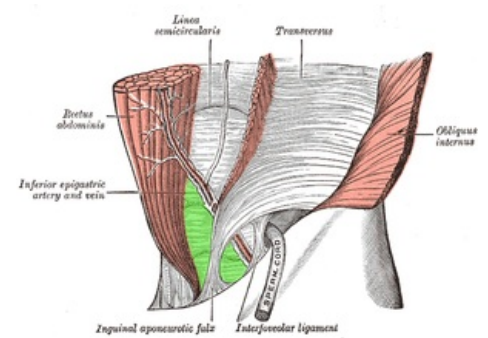
## Links

### Related articles

- Trigonum inguinale
- Obliquus internus abdominis muscle
- Abdominal muscles (table)

### References

- ČIHÁK, Radomír. *Anatomie 1*. 2. edition. Praha : Grada, 2001. 497 pp. ISBN 80-7169-970-5.
- KACHLÍK, David. *Katalog LF3 – Svaly* [online]. [cit. 2015-11-12]. <<http://katalog.lf3.cuni.cz/svaly/kategorie/346/?sestava>>.



Trigonum inguinale (green), falx inguinalis medially