

Fractures of the proximal femur

Fractures of the proximal femur (PF) are among the most frequent diagnoses in orthopedic and traumatological daily practice. In the Czech Republic, they affect around 11-15 thousand people every year. It mostly concerns **women in the 7th-8th decade**. These fractures are accompanied by **a number of serious complications**, which are a great burden for patients, and therefore are accompanied by a **high mortality rate**, which is widely related not only to medical care, but also to the quality of subsequent recovery and social background.

Fractures of the proximal femur are typical of **two distinct groups of patients**. The smaller first group consists mostly of young men after a traffic accident, sports injury or fall from a height (so-called **high-energy trauma**). The second larger group is usually made up of older women (around 78 years old on average) with a **history of falls** (at home or outside) without much violence. Due to the difference in the overall condition and quality of the bone tissue of these groups of patients, the therapeutic approach also differs significantly.

Anatomical connections

- The proximal femur consists of the **head', the neck and the trochanteric mass**. The neck touches the long axis of the femur at $125-135^\circ$ = **collodiaphyseal angle**.
- Here, the bone is mainly made up of spongiosa, which is made up of beams oriented according to the direction of the load. The cortex is thicker rather on the inner side - '**Adams' arch**'.
- Articular capsule strengthens the ligaments - **ligamentum iliofemorale', ischiofemorale' and pubofemorale'**.
- Vascular supply comes from **a. femoralis** through the branches of a. circumflexa femoris medialis and lateralis. **Only a small influence has a. ligamenti capitis femoris**.
- With the loss of cancellous tissue in connection with osteoporosis, a **locus minoris resistentiae** to the acting shearing forces is created here.

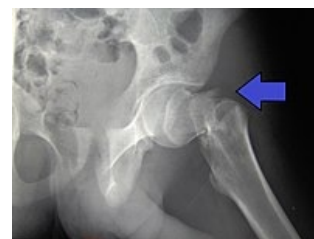Division

Head Fractures

- An uncommon type of fracture. Typical of a group of **young patients** with **high-energy violence** associated with dislocations and fractures of the acetabulum.
- They are separated in more detail by the so-called Pipkin classification.

Neck fractures

- Accounts for about half of PF fractures.
- According to the fracture line, we divide them into:
 - **intracapsular** (subcapital, mediocervical);
 - **extracapsular** (basicervical, lateral).
- Intracapsular fractures are '**dangerous**' from the point of view of a possible violation of the vascular supply, which leads to complications such as avascular necrosis or back joint.
- There are different '**evaluation classifications**' - according to Pauwels' (the course of the fracture line relative to the horizontal), according to Garden's (the risk of developing avascular necrosis according to bone trabecular damage).
- **Due to the risks, alloplasty** dominates the treatment.



Dislocated fracture of the neck of the L femur

Trochanteric fractures

- **Pertrochanteric** - the fracture line passes through the trochanteric massif.
- **Intertrochanteric** - the fracture line is between the greater and lesser trochanters.
- Makes up over half of PF fractures.
- **It heals** very well, complications such as avascular necrosis are rare.
- The treatment depends on the quality of the bone, dislocation and stability, it is usually solved by the osteosynthesis method.
- **They are classified according to AO classification**, forming groups **A1-A3**:
 - **A1'** - **simple** fracture, stable, without damage **to the arch of Adams** and the lateral cortex of the greater trochanter;
 - **A2'** - **comminuted** fracture, unstable according to the size of the broken **posteromedial fragment**, lateral cortex without damage;
 - **A3** - **intertrochanteric** fracture, unstable, fracture line runs through **both medial and lateral cortices**.

PF fractures can also occur on the basis of tumor processes such as **pathological**, or they can be accompanied by fractures of the femoral shaft.

Diagnostics

Visible shortening of the limb (can be up to several cm) and **external rotation** with **semiflexion** are already typical for PF fractures. The patient is lying down, unable to move a limb or walk. **There is palpable tenderness** on the front surface of the hip and in the region of the greater trochanter. (But none of these may be present in a wedged fracture.) The basis of the examination is **an X-ray** of the hip (in AP and axial projection) and an image of the entire pelvis (to exclude fractures of the pubic bones). In elderly patients, an X-ray image of the lungs is usually taken at the same time. US examination to detect hemarthrosis in intracapsular fractures.

Treatment

The treatment method can take several directions according to type of fracture, age, general condition, bone quality, skin condition, presence of inflammation, condition of hip joint, activities and mobility of the patient before the injury, cooperation skills.

- **Conservative treatment** - only for **stable wedge fractures** (but the risk of dislocation up to 60%). It is indicated for patients unable to move even before the injury or for patients for whom surgery is risky. However, conservative treatment is also a risk due to the complications of long-term immobilization associated with high mortality. If movement is possible, it is necessary to relieve the injured limb with crutches (up to 3 months).
- **Operative treatment** - indicated **for all displaced neck fractures and trochanter fractures**. It should take place immediately, preferably by the next day, if the general condition of the patient allows it. **Osteosynthesis** or **alloplasty** is performed.
 - Performance type is related to many circumstances such as: **dislocation, stability, slope of the fracture line, varus instability, age, state of the acetabula, arthrotic changes, momentum, general condition of the patient**, etc.

Osteosynthesis

Total endoprosthesis

The so-called dynamic hip screws (DHS = ``Dynamic hip screws; tension-cancellous and anti-rotational) and intramedullary hip nails'' (IMHN = intramedullary hip nails):

- for all trochanter fractures **'without the presence of arthrosis**;
- in displaced intracapsular fractures of the neck (in younger patients under 65);
- in non-dislocated intracapsular fractures of the neck (preventive against secondary dislocation in patients over 70 years old).

Alloplasty

Cervicocapital and total replacements are used:

- in displaced intracapsular fractures of the neck (in elderly patients over 65);
- for all fractures of the proximal femur **'with the presence of more advanced arthrosis**;
- in some pathological fractures.

Cervical capital compensation' (CCEP):

- easier, less burdensome performance;
- risk of acetabular damage from endoprosthesis head protrusion in active patients;
- indicated in elderly patients (over 80 years) with minimal demands for movement due to a poor biological condition;
- contraindications in arthrosis.

'Total replacement (TEP total endoprosthesis):

- more demanding, more taxing performance;
- better long-term function;
- indicated for intracapsular neck fractures of elderly patients (over 70 years) in good biological condition and for PF fractures with advanced arthrosis.

Follow-up care and complications

Postoperative care in PF fractures must be given particular attention to ensure proper healing and subsequent verticalization and mobilization of patients. **Postoperative mortality** is especially high in elderly patients in poor general condition. Follow-up care tends to be long-term, patients are not fully self-sufficient and are dependent on nursing and social care and family cooperation.

Complications that may occur, either general or local:

- pneumonia;
- infection, poor wound healing, urinary tract infection;
- development of immobilization syndrome, thrombophlebitis, TEN, embolization;
- decubitus.

Specific complications of PF healing:

- avascular necrosis of the femoral head;
- formation of deck joint;
- healing in varusitis.

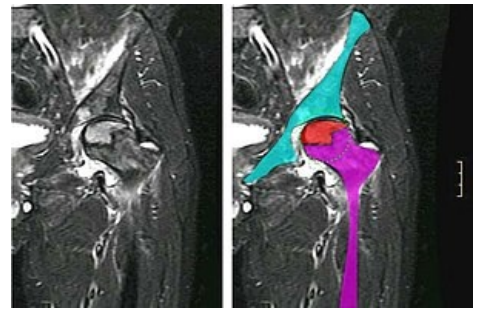
Links

External links

- **Anesthesia for hip TEP - interactive algorithm + test**

Related Articles

- Femur
- Fractures of the diaphysis of the femur
- Types of fractures and their dislocations
- Postoperative wound complications
- Osteosynthesis and its principles
- Alloplasty



MR avascular necrosis of the L femoral head

References

- ŽVÁK, Ivo. *Traumatologie ve schématech a RTG obrazech*. 1. edition. Grada, 2006. ISBN 80-247-1347-0.
- BARTONÍČEK, Jan. Zlomeniny proximálního femuru. *Postgraduální medicína* [online]. 2005, vol. -, p. 485-492, Available from <<https://zdravi.euro.cz/clanek/postgradualni-medicina/zlomeniny-proximalniho-femuru-168656>>. ISSN 1214-7664.
- HONZA, Petr. Zlomeniny proximálního femuru a jejich řešení. *Med. Pro Praxi* [online]. 2008, vol. 10, p. 393-397, Available from <<http://www.solen.cz/pdfs/med/2008/10/12.pdf>>. ISSN 1803-5310.