

# Epithelial tissue (classification according to the structure)

## Epithelial Tissue

Tissues are level of organizations. The next level after cell. Tissues used to build things, like organs.

Atoms - Molecule - Biomolecule - Organelles - Cell - TISSUES! - Organs - Organ System - Living organism

Tissue comprises a varied assembly of cells (around 200 different types in the human body) organized in a structured manner to collectively perform a specific function.

The human body consists primarily of four types of tissues: epithelial, connective, muscle, and nervous tissue. Organs are typically divided into two components: parenchyma, consisting of cells responsible for the primary functions specific to the organ, and stroma, which serves as the supportive tissue.

Epithelial tissue serves as a protective covering for surfaces and linings. • It forms a continuous layer of cells that envelops various spaces, such as the outermost layer of the skin, the lining of the oral cavity, and the interior of the digestive system. These cells are closely packed polyhedral cells, possessing minimal extracellular material. With strong adhesion properties, epithelial cells create cohesive sheets that cover bodily surfaces and line internal cavities. They establish boundaries between organs or between the body and its external surroundings, enduring repeated physical stress and injury. Epithelial tissue originates from all three germ layers:

- Ectoderm: Skin, oral cavity, nasal passages, and anal lining
- Mesoderm: Endothelium lining blood vessels
- Endoderm: Lining of the respiratory tract, gastrointestinal tract, and urinary bladder.

The majority of epithelial tissues are supported by connective tissue, referred to as the lamina propria within internal organs. The lamina propria not only offers structural support to the epithelium but also facilitates its nourishment and attachment to underlying structures. The contact area between these layers is often augmented by irregularities in the surface of the connective tissue, known as papillae. This phenomenon is most commonly observed in epithelial tissues that experience friction, such as the skin or the surface of the tongue.

## Characteristics of epithelial tissue:

1. Epithelial tissues line spaces through which substances enter or exit the body, serving as a barrier.
2. Due to their close packing, epithelial cells exhibit high cohesion, requiring significant mechanical force for separation.
3. Epithelial tissues are avascular, lacking a direct blood supply. Nutrients from blood vessels diffuse into epithelial cells, crossing the basal lamina into the underlying connective tissue.
4. Epithelial tissues display a high rate of cell division, facilitating constant renewal and repair through rapid mitotic activity.
5. The basal lamina, also known as the basement membrane, resides on the deep side of epithelial tissues. It comprises a mixture of proteins such as collagens, laminin, perlecan, and entactin, which form a highly crosslinked extracellular matrix.

## Basal Lamina (called 'basement membrane' under light microscope) has many functions:

- a. Filtering
- b. Influence cell polarity
- c. Regulate cell proliferation and differentiation by binding and concentrating growth factors
- d. Influence cell metabolism and survival
- e. Organize the proteins in the adjacent plasma membrane
- f. Serves as pathways for cell migration
- g. Information necessary for many cell-to-cell interactions

The basal lamina, approximately 100nm thick, plays a crucial role in attaching and anchoring cells to the underlying connective tissue. Proteins such as integrins and proteoglycans on the cell membranes bind to proteins within the basal lamina, which in turn connects to the extracellular matrix of the connective tissue.

Under electron microscopy, the basal lamina reveals three distinct layers:

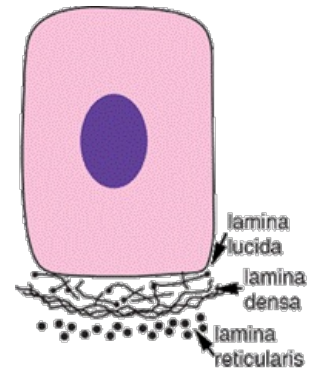
- Lamina lucida: A 40nm layer characterized by its electron-lucent appearance, showing minimal staining in electron microscopy. It contains laminin, and integrin proteins link desmosomes to the basal lamina.

- Lamina densa: This layer is electron-dense, measuring 40-60nm in thickness and primarily composed of Collagen IV.

- Lamina reticularis: Associated with reticular fibers of the underlying connective tissue, this layer connects to the connective tissue via anchoring fibrils (collagen VII) and fibrillin microfibrils.

6. Directional - Epithelial tissue exhibits polarity, featuring two distinct edges: the edge near the basal lamina is termed the "basal pole," while the opposite edge adjacent to the space is referred to as the "apical" or "luminal" pole. The lateral surfaces of the cell are the sides that face neighboring cells.

7. Cover or line - Epithelial tissue serves to cover or line various structures within the body, such as the heart or pericardium.



## Classification of Epithelial Tissue according to structure:

1. Planar – according cell shape, number of layers

2. Trabecular – cells are arranged in cords or plates (liver, endocrine glands)

3. Reticular – Cells are organized in three-dimensional network (stroma of thymus behind the sternum, epithelium of crypts in tonsils, stellate reticulum of enamel organ).

## Planar Classification:

Based on cell shape, the nuclear form often corresponds roughly to the cell shape. For instance, cuboidal cells typically have spherical nuclei, while squamous cells have flattened nuclei. The shape of the nuclei is useful for determining whether the cells are arranged in layers and identifying the type of epithelial cell. This distinction is aided by bold staining of the nuclei, which contrasts with the lipid-rich membranes between cells that are often indistinguishable with a light microscope. The three main types of cell shapes:

1. Squamos - flat thin cells & flat nuclei

2. Cuboidal

3. Columnar

## Classification according number of layers:

1. **Simple** – one layer of cells; Squamos, Cuboidal, Columnar

- 1a. Squamos – Diffusion.

- 1b. Cuboidal – Secretion

- 1c. Columnar – Secretion & Absorption

2. **Stratified** – More than one layer of cells;

- 2a. Stratified Squamos – all about protection

- 2b. Cuboidal - Secretion

- 2c. Transitional – change their shapes according to need.

3. **Pseudostratified** – Columnar cells, nuclei all over the place. No multiple layers – all the cells connect to the basal lamina membrane.

The superficial cells of stratified squamous epithelia can be either "keratinized" or "nonkeratinized." Keratinized cells are primarily found in the epidermis of the skin, which constitutes the outermost layer. In the inner layers of the epidermis, closer to the underlying connective tissue, the cells are typically cuboidal or low columnar in shape.

As these cells undergo keratinization, they gradually become irregular in shape and flatten. Accumulation of keratin occurs, and the cells are pushed toward the surface. Ultimately, they become thin, metabolically inactive, and lack nuclei. This outermost layer of cells plays a crucial role in protecting against water loss across the epithelium.

In contrast, non-keratinized cells line moist cavities, such as the mouth, esophagus, and vagina. In these regions where water loss is not a concern, the flattened cells of the epithelial surface layer remain living cells and contain much less keratin, retaining their nuclei.

**Stratified cuboidal and stratified columnar** epithelia are relatively uncommon.

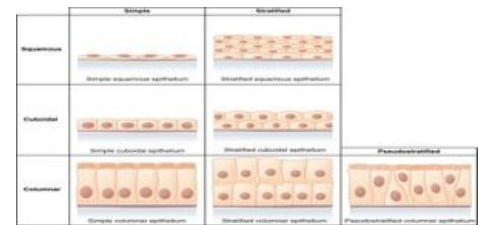
Stratified cuboidal epithelium can be found in the large excretory ducts of sweat and salivary glands. Stratified columnar epithelium is present in the lining of the eyelids, where it provides protection and secretes mucus.

**Transitional epithelium**, also known as urothelium, lines only the urinary bladder, the ureter, and the upper part of the urethra. It is characterized by a superficial layer of dome-like cells that are neither squamous nor columnar. These cells protect against the hypertonic and cytotoxic effects of urine. The shape of the surface cells changes according to the degree of swelling of the bladder wall, resembling that of pseudostratified columnar epithelium.

**Pseudostratified columnar epithelium** is so named because although all cells are attached to the basal lamina, their nuclei lie at different levels within the epithelium, and the height of some cells does not extend to the apical surface. This type of epithelium lines the passages of the upper respiratory tract. The majority of cells composing the ciliated pseudostratified columnar epithelium are of three types:

- Ciliated cells
- Goblet cells
- Basal cells.

**Ciliated cells** are columnar epithelial cells with specialized ciliary modifications. **Goblet cells**, named for their shape resembling a wine goblet, contain membrane-bound mucous granules and secrete mucus to maintain epithelial moisture and trap pathogens. **Basal cells** are small, nearly cuboidal cells believed to have the ability to differentiate into other cell types found within the epithelium.



## References

- JUNQUIERA, Anthony – MESCHER, . *Junqueira's Basic Histology*. 16. edition. McGraw Hill LLC, 2001. 576 pp. ISBN 1260462978.