

Disorders of tooth development

Disorders of tooth development can basically be divided into two categories:

- anomalies in the number, shape and size of teeth;
- disorders of the formation of hard dental tissues.

Etiology

In the case of developmental disorders of the teeth and the orofacial system, general and local influences are applied.

Overall influences

Here we include heredity, diseases threatening the fetus (rubella, syphilis), immunobiological processes, hypoxia, endocrine, metabolic and hormonal disorders. The influence of drugs (Thalidomide), alcohol, stress and others is also proven.

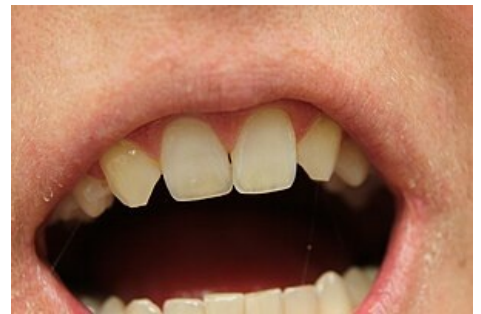Local influences

This mainly includes inflammation and trauma.

Anomalies of the number of teeth

They arise due to a violation of the activity of the dentogingival bar. According to the type of disorder, anomalies in the number of teeth are divided into different types:

- Agenesis – failure to establish one tooth.
- Hypodontia – a reduced number of teeth (fewer than 6 teeth are missing) – is caused by the arrest of the proliferation of the epithelial cells. The second upper incisors, third molars, and second premolars are most often missing.
- Oligodontia – more teeth will not be formed (6 or more teeth are missing). Oligodontia is usually part of syndromes such as ectodermal dysplasia, incontinentia pigmenti, cleft anomalies, Down syndrome, Rieger syndrome, EEC syndrome. Some other disorders of tooth development are also associated with it, such as delayed development and eruption, microdontia, cone-shaped teeth, infraocclusion of temporary molars, radix shortening, taurodontism, rotation of premolars and lateral incisors, hypoplasia, hypomineralization, and dentinogenesis imperfecta
- Anodontia – the dentition is not established.
- Hyperodontia – due to increased activity of the dentogingival bar, the formation and growth of supernumerary teeth (mesiodontes, dentes praelactales) occurs.



Hypodontia; second upper incisors missing

Therapy of anomalies of the number of teeth

We treat hypodontia in the permanent dentition with orthodontic treatment and subsequent prosthetic work. In the temporary dentition, treatment is usually not necessary.

Hyperodontia and dentes praelactales are most often solved by extraction.

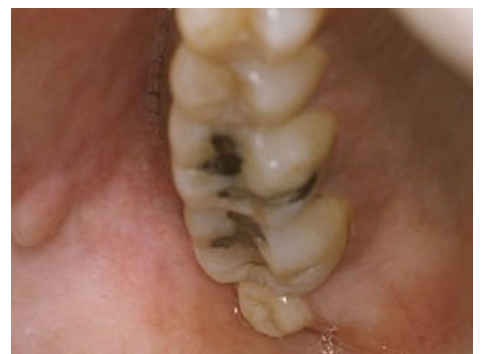Anomalies of tooth shape

- Macrodonia – excessively large teeth.
- Microdonia – proportionally small teeth.
- Fusion – failure of the embryo to split or the union of two tooth embryos.

Disorders of dental tissue formation

Disorders of dental tissue formation include non-specific changes in hard dental tissues, which are divided into three categories:

- hypoplasia;
- hypomineralization;
- dysplasia.



Microdontic tooth 18

Hypoplasia

Hypoplastic changes on the teeth are caused by the interruption or premature cessation of amelogenesis. Damage can occur during febrile conditions, diarrheal diseases, metabolic disorders... Hypoplastic teeth are characterized by a diverse appearance, pits, grooves. Enamel is thin, uneven, rough. The coloring is also atypical (yellow-brown to dark brown).

Hypomineralization

Hypomineralization occurs due to missing or insufficient initial calcification of the organic matrix. Spots on the labial surfaces of the frontal teeth are typical for teeth with hypomineralization. They are white or brownish in color. The enamel is shiny and smooth and the crown shape is normal.

Dysplasia

Dysplasias include fluorosis, tetracycline-induced dental changes, congenital illnesses, fetal erythroblastosis, hereditary disorders, amelogenesis imperfecta and dentinogenesis imperfecta.

■ Fluorosis

- The cause of fluorosis is the excessive intake of fluorides during intra-alveolar tooth development. It is manifested by white (chalky) spots on the enamel (mild form) and erosion with yellow-brown spots (severe form).

■ Tetracycline

- Tetracycline antibiotics administered in childhood cause changes in the teeth in both the temporary and permanent dentition. The dental tissue is colored mostly in the cervical part of the tooth, and it is yellowish brown.

■ Fetal erythroblastosis

- Changes in fetal erythroblastosis can again occur in both temporary and permanent dentition. The teeth are green, yellow or gray in color.

■ Congenital illnesses

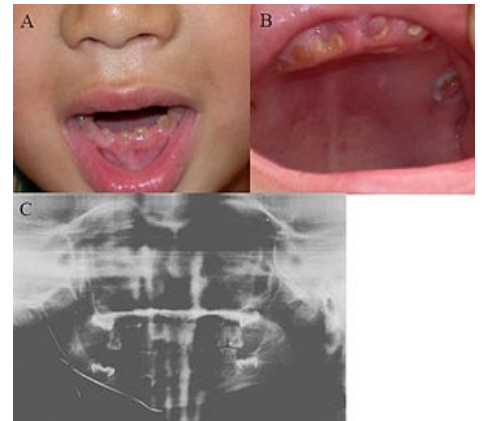
- The teeth have a characteristic anomalous shape (incisors – barrel-shaped, molars – mulberry-shaped, bud-shaped).

■ Hereditary Amelogenesis Imperfecta

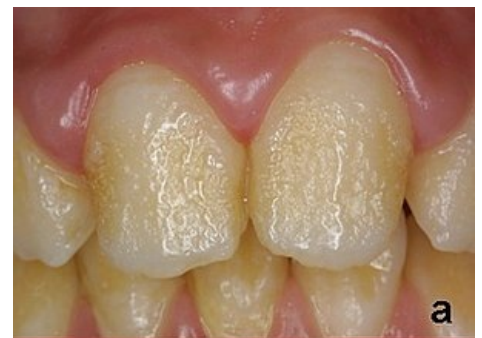- Hereditary amelogenesis imperfecta is a hereditary anomaly, it affects the entire dentition, the teeth are smaller, brown. Patients often suffer from tartar and plaque.

■ Hereditary Dentinogenesis Imperfecta

- Hereditary dentinogenesis imperfecta is a hereditary anomaly of permanent and temporary dentition. The teeth are yellowish to brown in color and easily subject to abrasion.



Amelogenesis imperfecta



Amelogenesis imperfecta

Treatment of developmental disorders of dental tissues

Treatment for developmental disorders is not always necessary. Teeth affected by hypomineralization usually do not require special treatment. Hypoplasia and dysplasia cause an unfavorable appearance, increase the risk of clinical crown fractures and increase tooth abrasion. We solve all these manifestations prosthetically. Less serious forms of hypoplasia and dysplasia can be treated with photocomposite materials. We pay extra attention to children with amelogenesis imperfecta (dental hygiene instructions) and regularly remove dental plaque and calculus.

Links

Related Articles

- Congenital dentin defects
- Development of teeth

References

- KOMÍNEK, Jaroslav. *Dětská stomatologie*. - edition. Avicenum, 1988.
- STEJSKALOVÁ, Jitka. *Konzervační zubní lékařství*. 2. edition. Praha : Galén, 2008. ISBN 978-80-7262-540-6..
- MERGLOVÁ, Vlasta – IVANČAKOVÁ, Romana. *Vývojové a získané poruchy zubů a tvrdých zubních tkání*. . 1. edition. Praha : Havlíček Brain Team, 2011. pp. 119. ISBN 978-80-87109-27-4.