

# Dermoidy

## Under construction / Forgotten

**This article was marked by its author as *Under construction*, but the last edit is older than 30 days.** If you want to edit this page, please try to contact its author first (you will find him in the history (<https://www.wikilectures.eu/index.php?title=Dermoidy&action=history>)). Watch the page as well. If the author will not continue in work, remove the template {{Under construction}} and the page.

Last update: Sunday, 25 Dec 2022 at 7.35 pm.

This article has been translated from WikiSkripta; ready for the **editor's review**.

**Dermoids** (dermoid cysts) are the most common skin tumors of teratogenic origin.

They occur mainly in the midline of the face. They are lined with skin epithelium and contain hair follicles, hair and sebaceous glands. They are firmly connected to the substratum, against skin they are free.

Nasal dermoids are hourglass shaped. Dermoids can also be found at the outer edge of the orbit.

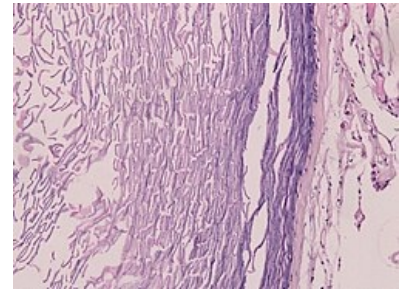
*Therapy* is surgical extirpation.

## Links

## References

■

Template:Stump



Dermoid cyst