

Cutaneous lymphoma

Primary cutaneous lymphomas include those that affect only the skin at the time of diagnosis.

Clinical picture

Non-specific and specific changes appear. Eczema and pruritus are classified as non-specific. Specific changes appear in about 17% of patients with malignant lymphoma. They arise on the basis of infiltration by tumor cells. The most common manifestation is infiltrated deposits anywhere on the body or solitary red-purple bumps in the groin.

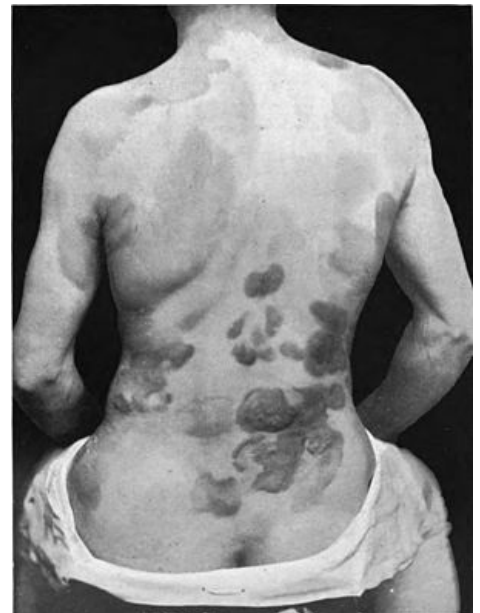
Classification of cutaneous lymphomas

Cutaneous T-lymphomas

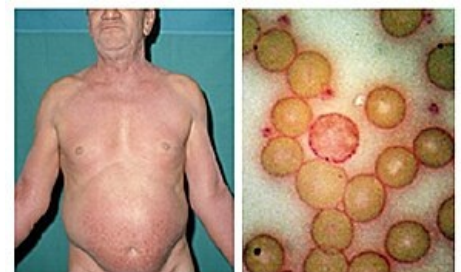Cutaneous T-lymphomas	Variants and subtypes
Mycosis fungoides	Folliculotropic MF
	Pagetoid reticulosis
	Granulomatous loose skin
Sézary syndrome	
Other cutaneous T-lymphomas	

Cutaneous B-lymphomas

Cutaneous B-lymphomas	Variants and subtypes
Primary cutaneous marginal zone B-lymphoma	
Primary cutaneous B-lymphoma from follicular centers	
Primary cutaneous diffuse large cell lymphoma of the lower extremities	
Primary cutaneous diffuse large cell lymphoma, other type	Intravascular large B-lymphoma



Mycosis Fungoides



Sézary syndrome

Links

Related Articles

- Lymphoma
- CNS lymphomas
- Hodgkin's lymphoma

References

- ŠTORK, Jiří. *Dermatovenerology*. 1. edition. Praha : Galén, Karolinum, 2008. 502 pp. ISBN 978-80-7262-371-6.