

Cubital Canal

It is the passage between the caput ulnare and the caput humerale m. flexoris carpi ulnaris and continuation of sulcus nervi ulnaris. In the *canalis cubitalis* n. ulnaris.

Delimitation of the entry of the nerve into the canal:

- **medially:** aponeurosis m. flexor carpi ulnaris;
- **laterally:** ligamentum collaterale ulnare;
- **ventrally:** epicondylus medialis.

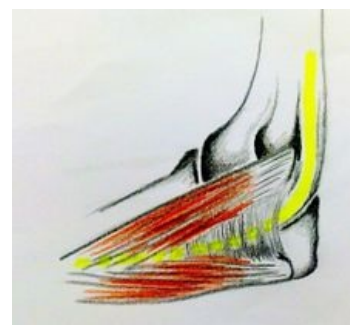
Links

Related Articles

- Humerus
- Ulnar nerve
- Cubital landscape
- Ulnar nerve palsy
- Articulatio cubiti

References

- MARTÍN ORTE, Emilio. *Atlas lidského těla v obrazech : anatomie, histologie, patologie. : anatomy, histology, pathology.* 1. edition. Rebo, 2008. 560 pp. ISBN 978-80-7234-896-1.
- GRIM, Miloš – DRUGA, Rastislav. *Základy anatomie, 5. Anatomie krajín těla.* 1. edition. Galen, 2002. 119 pp. ISBN 978-80-7262-179-8.



Bordered medially by the flexor carpi ulnaris muscle, it follows the sulcus of the ulnaris nerve and contents of the ulnar nerve