

Crystals

Crystals are **solid, rigid bodies, occurring either loosely in tissues or as components of stones.**

Examples of crystals

The crystals of uric acid

They are needle-shaped. They are most often found ' *in small joints (articular cartilage and synovial membranes) and in the subcutaneous tissue*' at the bottom (arthritis uratica) and in the **renal papilla** during aciduric infarction of the kidney. The crystals can be deposited extracellularly or intracellularly (in macrophages).

The source of uric acid can be both **endogenous production** (Biodegradation of purines), and **Exogenous** food supply (nucleoproteins). Increased production or decreased excretion results in hyperuricaemia, Which is the cause of gout. Its physiological **plasma concentration** (Uricaemia) is:


- in men 220–420 $\mu\text{mol/l}$
- in women 140–340 $\mu\text{mol/l}$

“Depending on the pH, **it occurs in the body as poorly soluble uric acid or as its sodium salt (sodium urate).For example, in plasma at pH = 7.4 it is in the form of about twenty times more soluble urate, in urine at pH below 5.8 it is in the form of less soluble acid.** {Arthritis uratica} for more information

Cholesterol crystals

Cholesterolové krystaly They take the form of either **diamond-shaped plates** or **pointed needles on both sides.**We find them for example:

- in interstitial (extracellular) steatosis
- in an Atherosclerotic plaque
- in post inflammatory pseudoxanthom
- and intracellularly in hepatocyte in cholestasis

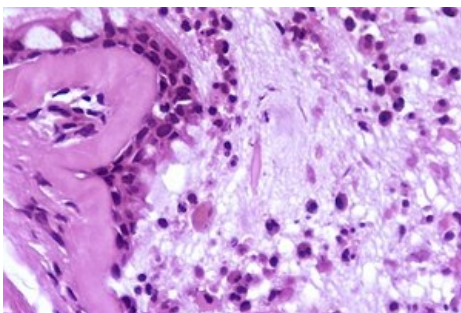


Numerous cholesterol crystals, as viewed in a direct microscopic examination of fresh synovial (joint) fluid, using crossed optical polarizers and a quarter-wave retarder plate. Cholesterol crystals are a rare finding in synovial fluid but have been reported in cases of rheumatoid arthritis. Cholesterol crystals are identified in medical specimens by their plate-like structures, which are often notched. They are much more commonly observed in urine.

Charcot-Leyden crystals

Astma bronchiale – in the middle of the preparation in the lumen visible Charcot-Leyden crystal formed by the decay of eosinophils

They have the shape of '*hexagonal needles. They are probably proteinaceous in nature. They occur wherever there is an increased breakdown of Eosinophils* (sites of allergic inflammation, around parasites.).



Crystals mucous substances

They are found in the '*places of multiplication of mucus*' (mucus dystrophy):

- ganglion – a cavity filled with mucus
- myxom – tumor of the mucous mesenchyme
- Paranasal sinuses etc..

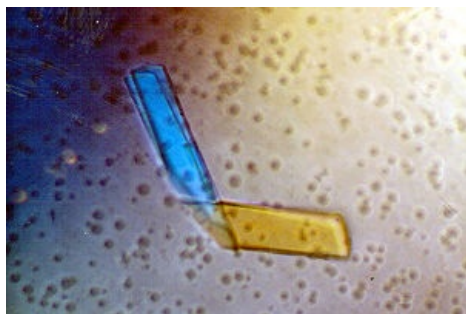
It stains markedly eosinophilically.

Paraprotein Crystals

náhled|300px|Krystal tvořen Bence-Jonesovým proteinem '*Paraproteins are plasma proteins, that does not normally occur*' in plasma. They are based on immunoglobulin chains. **Paraprotein crystals are deposited 'in the kidneys' in the lumen of the tubules as well as in the cells that line the tubules. They most often occur in** plasmacytic myeloma.

We distinguish several types of paraprotein crystals

- "'Bence-jones proteins -**consists of immunoglobulin light chains and is excreted in the urine**
- **Cryoglobulins** - are characterized by the fact that they crystallize in the cold (they can block, for example, blood flow through the limb)



Cystine crystals

They occur in **cystinosis** (an inherited disease characterized by the deposition of cystine crystals in cells of the monocyto-macrophage system). They occur in the bone marrow, liver, spleen, lymph nodes, kidneys,

cornea and other places. The most dangerous place for the storage is '*in the kidneys*', leading to renal failure renal failure.

'*Cystinuria*' is a disorder in the transport of cystine, lysine, arginine and ornithine, in which cystine stones are formed and deposited in the kidneys.

Oxalate crystals

náhled|300px|Kalcium oxalátové krystaly v moči They occur mainly **in the interstitium of the kidneys and myocardium in oxalosis**, which can be:

- **primary** -a congenital disorder in which the formation of oxalates increases, crystals also occur in the bone marrow
- **secondary** - Follows kidney damage from other causes (eg toxic damage, ethylene glycol poisoning)

Crystals of calcite (limestone - CaCO_3)

They occur in long-term hypoxic, stressed, or damaged tissue. Depositing into '*specific granulation tissue*' in TBC and especially sarkoidóze.

<References>

References

Related articles

- Arthritis uratica
- Lithiasis

source

- PASTOR, Jan. *Langenbeck's medical web page* [online]. [cit. 17.08.2009]. <<https://langenbeck.webs.com/>>.