

# Craniofacial syndromes

## Treacher-Collins syndrome (dysostosis mandibulofacialis)

- Autosomal dominant inheritance
- antimongoloid course of eye slits, colobomas of the eyelids, hypoplasia of the maxilla + mandible, bite disorders, macrostoma, bird profile, deformation of the auricles, developmental disorders of the middle ear, possibly also of the inner ear

## Pierre-Robin syndrome

- it is not hereditary
- cleft palate, hypoplasia of the mandible, sunken tongue during retrognathia → difficulty breathing and swallowing → breathing control required from birth / nasal intubation / "floating plate" palatal plate / suturing the base of the tongue into the vestibule of the lower lip sec Douglas. Micrognathia is definitively solved by osteodistraction of the mandible.

## Progressive hemifacial atrophy

- slowly progressing atrophy of the soft tissues of 1 side of the face
- affects skin, subcutaneous tissue, later also muscles and skeleton
- starts around age 20
- most likely caused by sympathetic damage → vasoconstriction, lipolysis, tissue atrophy

## Klippel-Feil syndrome (brevicollis)

- it is not hereditary
- without mental disability
- short neck with low-set hairline, deformity + fusion of C vertebrae, Pterygium colli, cleft palate, deformity of the auricles

## Dysmorphia otofaciocervicalis

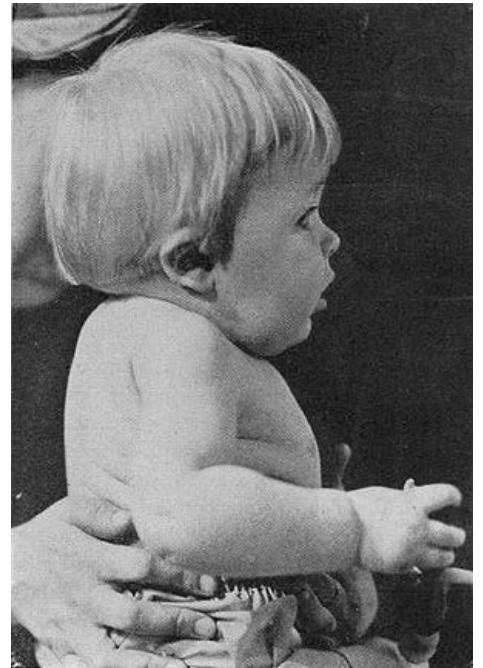
- anomalies of the outer, middle and inner ear, hypoplasia of the maxillozygomatic complex, cervical fistula, hypoplasia of the neck muscles → decrease in the arm girdle + pseudopterygium

## Dysmorphia palpebroorbitalis

- Ptosis of the upper eyelids, hypoplasia of the upper + lower eyelids, phimosis of the orbital fissure, epicantha, flattening of the supraorbital landscape, confluent eyebrows

## Dysmorphia craniocarpotarsalis ("whistling face" syndrome)

- narrowing of all facial meatus (mouth, nasal passages, eye slits, ear canals), anomalies of orbital structures, ptosis of upper eyelids, hypoplasia of upper + lower eyelids, epicantha, strabismus, enophthalmos, small nose, flattening of cheekbones, high philtrum, Gothic palate, arthrogyrosis, pes equinovarus, umbilical hernia + inguinal hernia, scoliosis, skin defects, hyperhidrosis and other



Klippel-Feilův syndrom

## Defect of skull cap and amniotic strangulation

- partial defect of hard and soft coverings of the top of the head + amniotic strangulation, possibly loss of fingers or entire limbs

## Sedláček's syndrome

- syndrome of developmental shortening of the palate
- palatolalia, wide nasal root, narrow eye slits, narrowed nasal and auditory canal entrances, hypomimia, short upper lip, short hypoplastic pinnae, mental retardation, cleft palate and others

## Links

## Used literature

- MĚŠTÁK, Jan. *Úvod do plastické chirurgie*. 1. edition. Univerzita Karlova v Praze - Nakladatelství Karolinum, 2005. 125 pp. ISBN 80-246-1150-3.