

Connection to the skull

Connections on the skull include synchondroses cranii (cranial synchondroses), suturae cranii (cranial sutures), ligamenta and articulatio temporomandibularis (jaw joint).

Synchondroses cranii

Cranial Synchondroses are parts of the skull base that have not ossified. The original cartilage from prenatal development persists here. Some of them remain preserved throughout life.

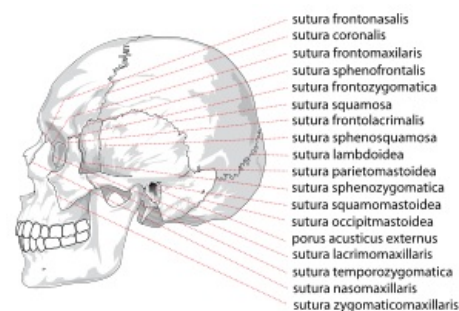
- **Synchondroses sphenopetrosa a petrooccipitalis** – connect the petrous bone ventrolaterally with the sphenoid bone and dorsomedially with the occipital bone, these synchondroses are preserved throughout life.
- **Synchondroses intraoccipitalis anterior et posterior** – lie between the individual bases of the occipital bone, disappear by the 4th–7th. year of life.
- **Synchondrosis intersphenoidalis** – connects the two halves of the body of the sphenoid bone, occurs between the 8th month and the 6th year.* **Synchondrosis sphenoccipitalis** – connects the sphenoid and occipital bones, lasts the longest of all synchondroses, up to the 18th–20th century. year of life.

Suturae cranii

Suturae cranii, or cranial sutures, are **fibrous connections** of individual flat bones of the skull. This type of connection is found **exclusively on the skull** and is completely typical for it. During the growth period, the seams serve as places for bone growth into the area. The ligament within the suture is either a derivative perichondria kostí osifikujících bone, or it originates from the edges of the endesmally ossifying bone. The arrangement of the joint line is different, from a smooth course to complex interdigitation of saw-like seams.

The most prominent sutures on the skull include:

- **Sutura sagittalis** – an arrow-shaped seam, connects the parietal bones to each other, the sagittal plane that divides the body into right and left halves is named after him.
- **Sutura coronalis** – coronal suture, connects the frontal bone with both parietal bones, the coronal plane is named after it, which divides the body into ventral and dorsal halves, this plane is the same as the frontal plane.
- **Sutura lambdoidea** – lambda suture, connects the occipital bone with the parietal bones.
- **Sutura squamosa** – scaly seam, connects the scale of the temporal bone (squama ossis temporalis) to the parietal bone.
- **Sutura intermaxillaris** – a seam that connects the upper jaws (maxillae), the upper jaw is therefore made up of two bones, unlike the lower jaw.
- **Sutura metopica** – the seam that connects the left and right bases of the future frontal bone on the newborn's skull, runs vertically upwards above the root of the nose in the middle of the forehead.



Sutures cranii

Ligaments on the skull

We do not find many ligaments on the skull itself. Practically the only separate ligament is **ligamentum stylohyoideum**, which connects the styloid process on the temporal bone with the small horns jazyčky.

In adulthood, small bones may appear in the ligament. This ligament therefore connects the tongue to the skull and allows it to be counted among the bones of the skull. Other ligaments are part of the jaw joint (articulatio temporomandibularis) and are therefore described together with the joint.

Odkazy

Související články

- Neurocranial Bones
- Splachnocranial Bones
- Skull of a newborn
- Connection of bones

References

- WEIGNER, Karel. *Topographical anatomy with regard to the study of anatomy and clinical needs: : Part 1, topographical anatomy of the head - cranial part..* 3. edition. Springer, 1930. 424 pp.
- ČIHÁK, Radomír. *Anatomie 1.* 2. edition. Grada Publishing, a. s., 2001. 516 pp. ISBN 80-7169-970-5.