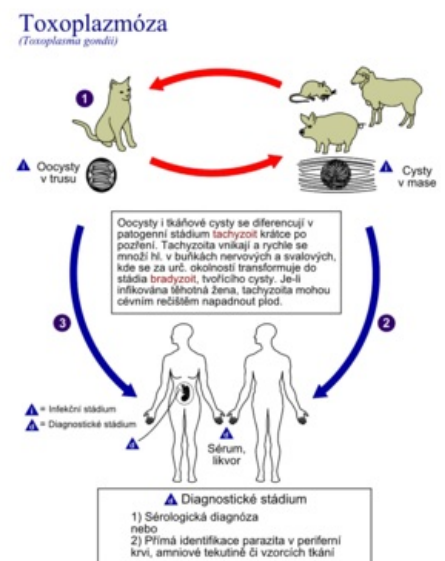


# Congenital toxoplasmosis

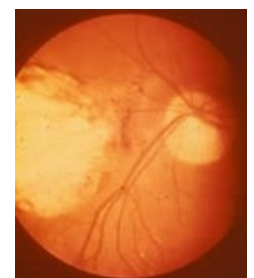
Toxoplasmosis is a parasitic disease caused by the protozoan *Toxoplasma gondii*. It is a fetal-threatening infection (STORCH) - it can cause severe damage to the fetus. Toxoplasmosis is transmitted to the fetus mainly during primoinfection of the pregnant woman and the risk of transmission from the pregnant woman to the fetus increases with gestational age. Infection early in pregnancy has the most serious consequences. The clinical picture of congenital toxoplasmosis most commonly includes chorioretinitis (present in 92% of children severely affected by congenital toxoplasmosis), intracranial calcification (in 80%) and hydrocephalus (in 68%), with the so-called Sabin's triad being reported when present. Toxoplasmosis can be detected serologically and by PCR (from amniotic fluid, blood, liquor, urine and other body fluids). Pyrimethamine, sulfadiazine and folic acid are used for treatment.<sup>[1]</sup> Serological screening of pregnant women for toxoplasmosis is not established in the Czech Republic.

## Etiopathogenesis

- originator: *Toxoplasma gondii*;
  - an obligate intracellular parasite, widespread worldwide;
  - infects humans and a wide range of animals and birds;
  - has 3 infectious stages:
    1. tachyzoite - responsible for the rapid spread between cells and tissues and for the clinical manifestation;
    2. bradyzoite - in resting-stage tissue cysts until severe host immunocompromise occurs;
    3. sporozoite - in oocysts in felids, ensures spread of parasites through the environment;
  - By genotyping, three main strains (types 1-3) and atypical and more virulent strains (mainly distributed in North and South America) can be distinguished; in Western Europe, type 2 predominates;<sup>[1]</sup>
- infection of pregnant women: ingestion of oocysts in contaminated food, water or soil or ingestion of tissue cysts in infected undercooked meat (tissue cysts can be inactivated by cooking or deep freezing);<sup>[1]</sup>
- it is estimated that 50-80% of all pregnant women have not yet contracted toxoplasmosis and are therefore at risk of infection;
- the course of primoinfection in pregnant women is inapparent in 75%.<sup>[2]</sup>
- transplacental transmission may occur in parasitaemia during primoinfection in pregnancy; about 40-50%<sup>[3]</sup> of fetuses become infected;
- possibilities of transmission of infection to the fetus:
  - from an initially seronegative, immunocompetent mother who experiences primoinfection during pregnancy or less than 3 months before conception;
  - reactivation of toxoplasmosis in an initially *Toxoplasma gondii*-immune woman who becomes severely immunocompromised during pregnancy;
  - reinfection of an initially immune woman with a more virulent strain (e.g. during travel);<sup>[1]</sup>
- the risk of transmission to the fetus increases with the stage of pregnancy; it is also increased with immunosuppression, with increased virulence of *T. gondii* and with increased viral load.<sup>[1]</sup>



Life cycle of *Toxoplasma gondii*



Toxoplasma chorioretinitis

## Clinical picture

- the earlier in pregnancy the mother's illness takes place, the greater the damage to the fetus (spontaneous abortion, stillbirth, child affected by Sabin's triad);
- the clinical picture of congenital toxoplasmosis is dominated by CNS and retinal involvement:
  - encephalomyelitis with formation of malignant foci in the CNS with subsequent hydrocephalus, calcification in the brain;
  - ocular involvement in the form of chorioretinitis, possibly microphthalmos to anophthalmos, usually unilateral;
- furthermore, any organ in the body can be affected;
- a seemingly healthy child may be born, but the disease does not start to manifest itself until between the ages of 2-5 - e.g. visual disturbances (squinting), mild retardation, minor calcifications on the brain, etc;
- a completely healthy child.<sup>[4]</sup>
- The so-called **Sabine Trias** or **tetrad**:
  1. chorioretinitis (about 15% of cases; more often bilateral);<sup>[5]</sup>
  2. cerebral calcifications (about 10% of cases);<sup>[5]</sup>
  3. hydrocephalus;

- 4. convulsions;
  - further: microcephalus, anaemia, hepatosplenomegaly, fever, organ cysts,...<sup>[3]</sup>

The classical Sabin triad is present in only 2%. Most often, babies are infected subclinically at birth. In the neonatal period, there may be fevers, convulsions and prolonged icterus. The most common is the latent course, in which the damage becomes apparent only in childhood or adolescence: chorioretinitis, strabismus, deafness, psychomotor retardation, epilepsy.<sup>[2]</sup>

Newborns with congenital toxoplasmosis have anaemia, thrombocytopenia and hyperbilirubinemia.<sup>[5]</sup>

## Diagnostics

- Immunoglobulin testing of IgM, IgG, IgA, avidity or IgE classes in both the child and mother; repeated IgG levels against toxoplasma; IgM have low sensitivity;<sup>[3]</sup> a significant proportion of children with congenital toxoplasmosis do not have detectable specific IgM antibodies at birth and in early childhood;<sup>[5]</sup>
  - complement fixation reaction (CFR);<sup>[4]</sup>
  - PCR - PCR testing of amniotic fluid can be performed from 16 weeks onwards to diagnose fetal infection;<sup>[2]</sup>
  - ophthalmological examination; brain ultrasound; lumbar puncture;<sup>[4]</sup>
  - diagnostic criteria for congenital toxoplasmosis (according to the American Academy of Pediatrics):
    - persistence of positive IgG antibodies after 12 months of age (gold standard);
    - positive IgG and positive IgM and/or IgA antibodies;
    - positive PCR from amniotic fluid, peripheral blood, cerebrospinal fluid, urine or other body fluid;
    - positive neonatal IgG antibodies (but negative IgM and IgA) and serologically proven acute maternal infection during pregnancy and clinical manifestations consistent with congenital toxoplasmosis.<sup>[1]</sup>
  - clinical examination of children with suspected congenital toxoplasmosis:
    - detailed physical examination, neurological and ophthalmological examination, BAEP (brainstem auditory evoked responses) hearing test;
    - head ultrasound or CT scan, abdominal ultrasound;
  - when unclear, a series of IgG antibody titres every 4-6 weeks from birth until complete resolution.<sup>[1]</sup>
- 
- The obligation to test for toxoplasmosis in pregnancy is not established in the Czech Republic;
  - if a low anamnestic IgG antibody titre with high avidity indicative of latent infection is found at the beginning of pregnancy, it is not necessary to monitor the pregnant woman further;
  - women who do not have antibodies should continue to be monitored during pregnancy to catch possible asymptomatic primoinfection - high titres of IgM, IgA and IgE antibodies and low avidity of IgG antibodies.<sup>[2]</sup>

## Treatment

- pyrimethamine, sulfadiazine and folic acid for 12 months;<sup>[1]</sup>
- in severe chorioretinitis or elevated cerebrospinal fluid protein levels, consider adding corticosteroids after 72 hours of antitoxoplasma therapy;<sup>[1]</sup>
- antenatal treatment: spiramycin (up to 15 weeks gestational age), pyrimethamine and sulfadiazine (from 16 weeks gestational age).<sup>[6]</sup>

## Links

### Related articles

- Toxoplasmosis
- Infections threatening the fetus: congenital syphilis • congenital listeriosis • HBsAg-positive mother and newborn • HIV infection in pregnancy • importance of chlamydia and mycoplasmas in perinatology • congenital cytomegalovirus infection • adenatal HSV infection
- Infections in the neonatal period

### Reference

1. MALDONADO, Y A – READ, J S. *Diagnosis, Treatment, and Prevention of Congenital Toxoplasmosis in the United States* [online]. American Academy of Pediatrics, ©2017. [cit. 2018-08-22]. <<http://pediatrics.aappublications.org/content/early/2017/01/26/peds.2016-3860>>.
2. MACHALA, L. TOXOPLAZMÓZA. *Interní medicína pro praxi* [online]. 2005, vol. 3, p. 120-122, Available from <<https://www.internimedicina.cz/pdfs/int/2005/03/03.pdf>>.
3. LEBL, J – JANDA, J – POHUNEK, P, et al. *Klinická pediatrie*. 1. edition. Galén, 2012. 698 pp. pp. 8-10. ISBN 978-80-7262-772-1.
4. FUSKOVÁ, E. TOXOPLAZMÓZA V DĚTSKÉM VĚKU. *Pediatr. praxi* [online]. 2003, vol. 6, p. 312-313, Available from <<https://www.pediatriepropraxi.cz/pdfs/ped/2003/06/04.pdf>>.
5. HÖKELEK, M. *Toxoplasmosis* [online]. Medscape, ©2013. [cit. 2013-05-30]. <<https://emedicine.medscape.com/article/229969-overview>>.

6. MUNTAU, Ania Carolina. *Pediatric*. 4. edition. Praha : Grada, 2009. pp. 32-34. ISBN 978-80-247-2525-3.