

Clavipectoral Triangle

English: *Clavipetoral triangle, deltopectoral triangle*

Latin: *Trigonum clavipectorale*



The **clavipectoral** or **deltopectoral triangle** (lat. *trigonum clavipectorale*) is an anatomical triangle bordered by the following structures:

- pectoralis major muscle;
- deltoid muscle;
- clavicle.

It contains the cephalic vein, thoracoacromial artery and pectoral nerves.

Links

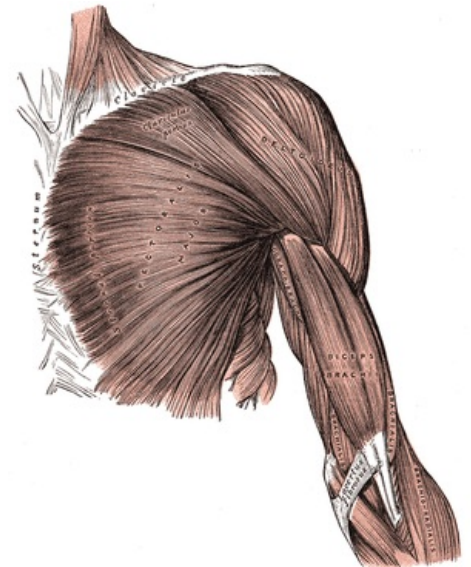
Related articles

External links

- SUNY Labs - Deltopectoral Triangle (<http://ect.downstate.edu/courseware/haonline/labs/l04/030101.htm>)

Bibliography

- PETROVICKY, Pavel, et al. *Anatomie s topografií a klinickými aplikacemi : Sv. 1, Pohybové ústrojí. 1.* edition. Martin : Osveta, 2001. 463 pp. ISBN 80-8063-046-1.



Superficial muscles of the upper limb