

Category:Anatomy

Subcategories

This category has only the following subcategory.

B

- Bones (2 P)

Pages in category "Anatomy"

The following 200 pages are in this category, out of 638 total.

(previous page) (next page)

A

- Abdominal aorta
- Abdominal muscles
- Abdominal Pain
- Abruptio
- Accessory sex glands
- Adductor brevis muscle
- Adductor Canal
- Adductor Hiatus
- Adductor longus muscle
- Adductor magnus muscle
- Aditus pelvis.jpeg
- Adrenal glands
- Amelogenesis imperfecta
- Portal:Anatomy
- Ankylosis
- Anterior cervical triangle
- Anterior Cervical Triangle
- Aorta
- Aorta abdominalis
- Aorta thoracica
- Apocrine glands
- Arch of the foot
- Arteria axillaris
- Arteria carotis externa
- Arteria lusoria
- Arteria radialis
- Arteria ulnaris
- Arteries of the lower limbs
- Arteries of the Upper Limb
- Auditory pathway
- Axial Skeleton
- Axilla
- Axillary nerve palsy
- Axon

B

- Basal ganglia
- Basilic hiatus
- Biceps femoris muscle
- Bile
- Biliary tract
- Biomechanics
- Biomechanics of the knee joint
- Blood flow in the kidneys
- Blood-brain barrier
- Body hair and hair
- Bone
- Bone age
- Bone growth and healing
- Bone marrow
- Bone structure and remodeling

- Bone structure and remodeling
- Bones of the lower limb
- Bones of the thorax, connections, motility of the ribs
- Bones of the upper limb
- Bottom jaw
- Brachial artery
- Brain Development
- Bécclard's angle

C

- Calot's Triangle
- Canalis pudendalis
- Capillary
- Cardiac conduction system
- Cardiac silhouette
- Cardiomyocyte
- Carotid Triangle
- Carpal bones
- Carpal Tunnel
- Carpal tunnel syndrome
- Cartilage
- Cavocaval anastomosis
- Cementum
- Cerebellum
- Cerebrospinal Fluid
- Cerebrospinal fluid circulation
- Cervical fascia
- Cervical neurovascular bundle
- Cervical plexus
- Cervical Sympathetic System
- Cervix (cervix uteri)
- Chest Muscles
- Chopart's joint
- Chronic nerve compression syndromes (entrapment), peripheral nerve tumors
- Ciliary ganglion
- Circle of Willis
- Circulatory system
- Clavicle
- Clavipectoral Triangle
- Clinostasis
- Commissural junctions in the brain
- Common peroneus nerve palsy
- Common tendon ring
- Concha nasalis inferior
- Connection of bones
- Connection to the skull
- Cornea
- Coronary circulation
- Corticospinal tract
- Cranial nerves
- Cremasteric reflex
- Cubital Canal
- Cubital Fossa
- Curvature of the spine
- Cytoarchitectonics of the brain cortex

D

- Deltoid Muscle
- Dendrite
- Dentinal tubules
- Dentinum
- Descent of Testis
- Desmogenous ossification
- Development of the cardiovascular system
- Development of the duodenum
- Development of the genitourinary system
- Development of the heart
- Development of the olfactory apparatus
- Development of the spinal cord
- Development of the urinary system
- Development, ossification and variation of the pelvic bone
- Developmental defects of the branchial region
- Dextrocardia

- Diaphragm
- Diaphragmatic hernia
- Diaphysis
- Diencephalon
- Digastric Muscle
- Discus articularis
- Douglas pouch
- Ductus deferens
- Duodenum

E

- Ear
- Eccrine sweat glands
- Ectopic pregnancy
- Ejaculation
- Embryonic Development of Muscles
- Enamel
- Endocardium
- Endochondral ossification
- Epicanthus
- Epicardium
- Epididymis
- Epigastrium
- Epiglottis
- Epiphysis
- Epiphysis (part of bone)
- Eponyms in anatomy
- Esophagus
- Ethmoid bone
- Eustachian tube
- Excretory ducts in the male reproductive system
- Extensor digitorum longus muscle
- Extensor hallucis brevis muscle
- External Carotid Artery
- External carotid artery
- External Iliac Artery
- Eye (biophysics)/Disorders of the eye
- Eye (biophysics)/Principle of vision

F

- Facial Nerve
- Falx inguinalis
- Female genital system (histology)
- Female genitalia
- Female reproductive system
- Femoral Artery
- Femoral hernia
- Femoral nerve palsy
- Femoral Triangle
- Fetal Circulation
- Fibrae dentini
- Fibula
- Finger bones
- First lower premolar
- Foramen omentale
- Formations behind the lateral ankle
- Formations behind the medial ankle
- Formations in front of the medial ankle
- Fossa ischioanal
- Free motor skills
- Frontal bone
- Function of the spinal cord
- Function of the urinary tract

G

- Galea aponeurotica
- Gallbladder
- Gallbladder and Extrahepatic Bile Ducts
- General anatomy of the lymphatic system
- General structure of autonomic nerv system
- General structure of nervous tissue
- General structure of the alimentary canal

- Geniohyoid muscle
- Gerota's Fascia
- Glandulae vesiculosae
- Glossopharyngeal Nerve
- Golgi tendon body
- Gracilis muscle
- Guyon's canal

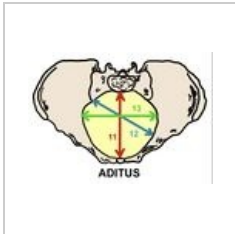
H

- Hammock principle
- Hand joints
- Hand tendon injury
- Hard dental tissues
- Head fascia
- Head parasympathetic
- Head's zones
- Heart
- Heart valves
- Hematoencephalic barrier


(previous page) (next page)

Media in category "Anatomy"

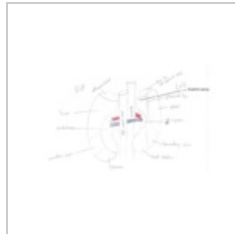The following 40 files are in this category, out of 40 total.



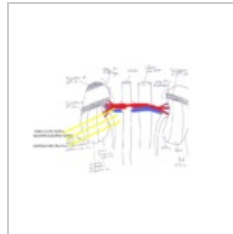
Aditus pelvis.jpeg
791 × 558; 100 KB



Anatomie.png
50 × 50; 5 KB



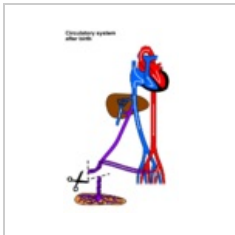Anatomy-urogeni...
628 × 373; 65 KB



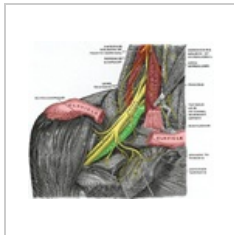
Anatomy-urogeni...
725 × 436; 121 KB



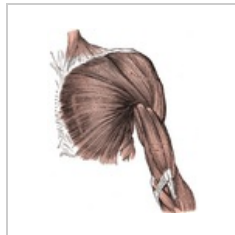
Circulation fetal...
500 × 800; 40 KB



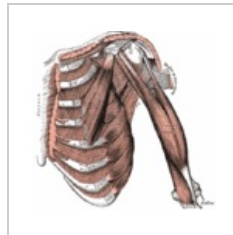Circulation neona...
500 × 800; 40 KB



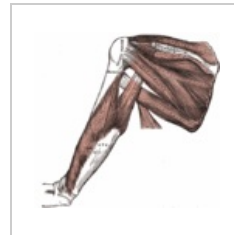Fissura scalenoru...
575 × 488; 489 KB



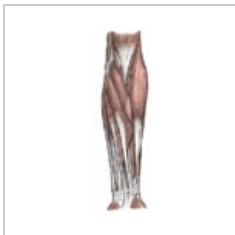Gray410.png
531 × 650; 125 KB



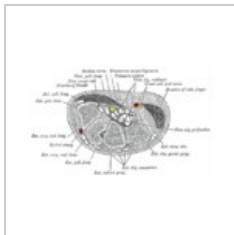
Gray411.gif
550 × 533; 76 KB



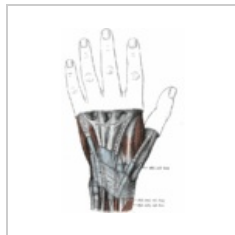Gray412.gif
550 × 523; 51 KB



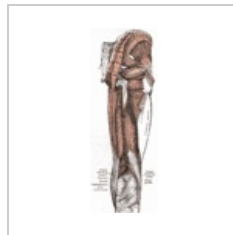Gray414.gif
227 × 700; 46 KB



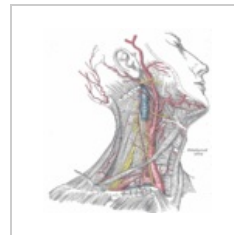
Gray422.gif
650 × 386; 46 KB



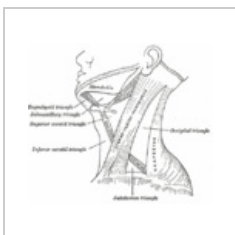
Gray424.gif
467 × 700; 50 KB



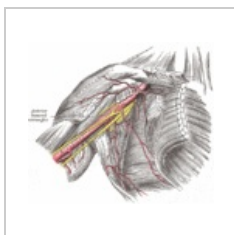
Gray434.gif
368 × 1,000; 117 KB



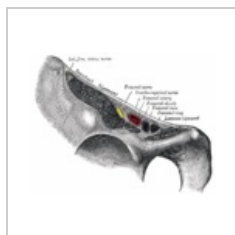
Gray507.gif
725 × 800; 186 KB



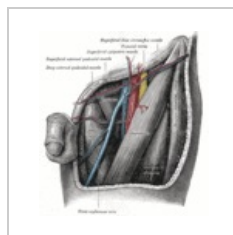
Gray512.gif
500 × 433; 40 KB



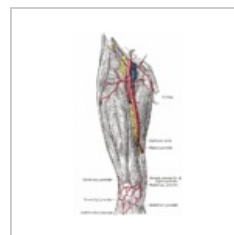
Gray523.gif
683 × 600; 125 KB



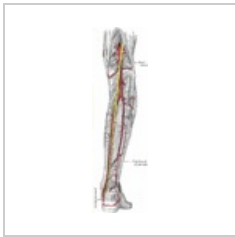
Gray546.gif
500 × 385; 59 KB



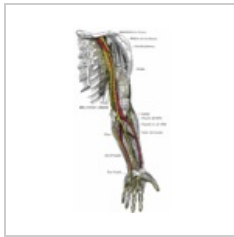Gray549.gif
550 × 600; 147 KB



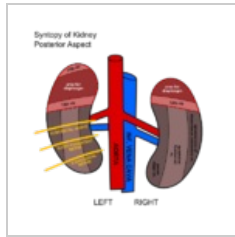
Gray550.gif
445 × 750; 99 KB



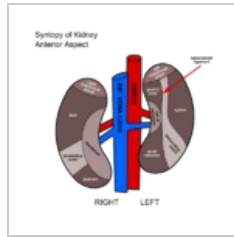
Gray551.gif
275 × 900; 101 KB



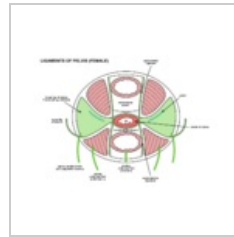
Gray816.gif
524 × 1,000; 112 KB



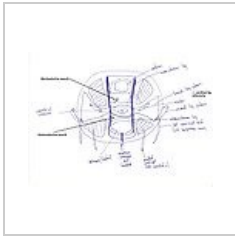
Kidney syntopy b...
480 × 480; 70 KB



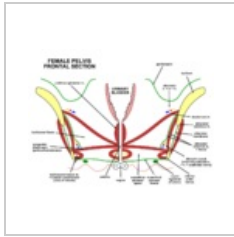
Kidney syntopy.p...
480 × 480; 62 KB



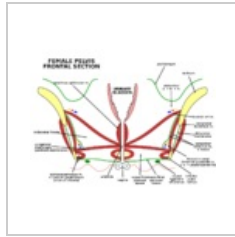
Ligaments of pel...
900 × 640; 60 KB



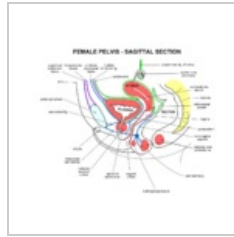
Ligamentsofpelvi...
2,338 × 1,700; 531 KB



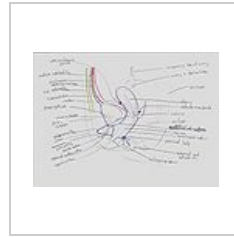Pelvis-female fro...
1,024 × 768; 233 KB



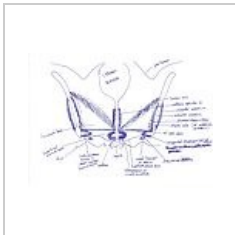
Pelvis-female fro...
1,024 × 768; 60 KB



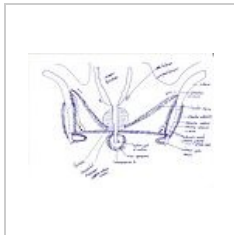
Pelvis-female sag...
960 × 800; 234 KB



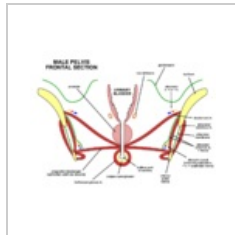
Pelvis-female-sa...
2,338 × 1,700; 814 KB



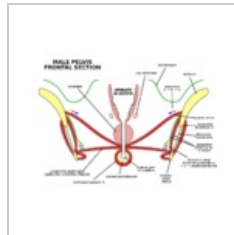
Pelvis-frontalsect...
2,338 × 1,700; 900 KB



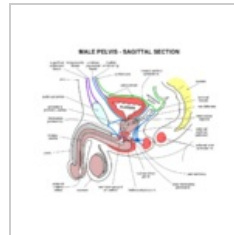
Pelvis-frontalsect...
2,338 × 1,700; 880 KB



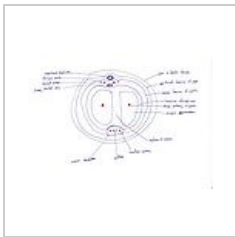
Pelvis-male front...
1,024 × 768; 207 KB



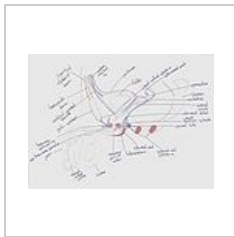
Pelvis-male front...
1,024 × 768; 50 KB



Pelvis-male sagit...
960 × 800; 274 KB



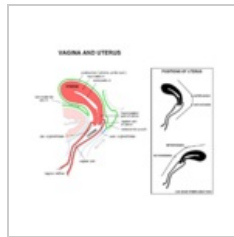
Penis-xsection.jpg
2,338 × 1,700; 355 KB



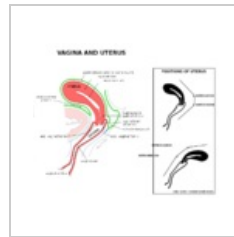
Pelvis-male-sagit...
2,338 × 1,700; 748 KB



Uterus+vagina.jpg
1,912 × 941; 359 KB



Vagina uterus.png
960 × 800; 160 KB



Vagina uterus.svg
960 × 800; 64 KB