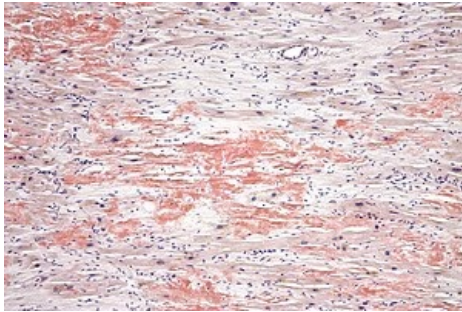


# Cardiac Amyloidosis

**Cardiac amyloidosis** is an infiltrative disease characterized by amyloid deposition in the extracellular spaces of the myocardium. It can be part of a systemic amyloid disease or develop independently. The clinical picture varies depending on which organ is affected. In the case of the heart, symptoms are mainly those of unilateral or even biventricular **heart failure**. The diagnosis is based on the results of biochemical tests, imaging and biopsy methods.

## Etiopathogenesis



Cardiac amyloidosis with extracellular amyloid deposits (red clusters, Congo red staining)

Amyloidosis is a **systemic infiltrative disease associated with the deposition of insoluble forms of proteins (amyloid) in the extracellular spaces of tissues** of various organs, including the heart. It is one of the most common causes of the development of restrictive cardiomyopathy. Amyloidoses are classified into several types based on the amyloid precursor proteins. The most common types are AL and TTR amyloidosis.

In **AL amyloidosis**, deposition of monoclonal kappa or lambda light chain occurs. The amyloid precursor proteins are produced by defective plasma cells. It may be accompanied by multiple myeloma. In any case, some type of monoclonal gammopathy is present in these patients.

**TTR amyloidosis** (TTR protein is produced primarily in the liver) is divided into senile, where the precursor is wild-type transthyretin, and familial, where the precursor is a mutant TTR protein. Transthyretin

physiologically serves as a transporter of thyroid hormones and vitamin A derivatives.

## Clinical picture

The clinical picture of the different types of cardiac amyloidosis is **heterogeneous**. In general, the predominant symptoms are signs of **biventricular heart failure**, reduced exercise tolerance and low blood pressure. On physical examination, pleural effusion, hepatomegaly and ascites are often observed. In some cases, a history of bilateral carpal tunnel syndrome or rupture of the musculus biceps brachii tendon may indicate amyloidosis.

**AL amyloidosis** is most commonly manifested **after the age of 50** and affects all organ systems except the CNS. The heart is affected in 50% of cases. Clinically, this type presents with rapidly progressive bilateral heart failure with a predominance of right-sided manifestations. Patients also describe angiotic symptoms (due to amyloid deposition in the vessel walls).

**Senile TTR amyloidosis** in turn primarily affects the heart. In the familial form, the heart is also predominantly affected, along with the peripheral and autonomic nervous systems. Senile TTR amyloidosis manifests mainly after the age of 70 (but the diagnosis **around the age of 40** is not uncommon).

**Familial amyloidosis** is an autosomal dominant disease with high penetrance. The gene encoding the TTR protein is mutated. It primarily manifests as neuropathy and very often as cardiac involvement, which is also influenced by the specific type of mutation (in some mutations the primary involvement is cardiovascular or neurological, or mixed). The disease first appears in patients in a wide range of ages from **20 to 70+ years**.

## Diagnostics

The diagnosis of amyloidosis is based on **clinical picture and analysis of blood and biopsy samples**. In differentiating the type of amyloidosis, the examination of **serum free kappa or lambda light chain** (AL amyloidosis) is important. The definitive diagnosis is based on **evaluation of the biopsy specimen**. In the case of cardiac muscle involvement, it is not always necessary for the patient to undergo an endomyocardial biopsy. According to current diagnostic criteria, biopsy verification in extracardiac tissue (in the presence of signs of cardiac involvement clinically, on imaging, or in the laboratory) is sufficient. Endomyocardial biopsy is therefore used more in suspected isolated cardiac amyloidosis or in other specific situations.

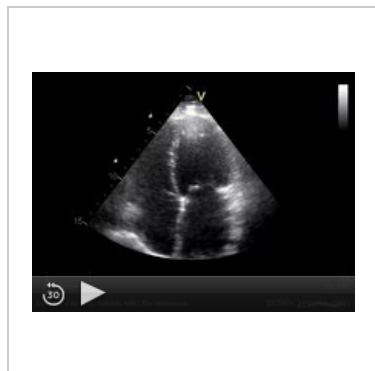The specific type of amyloidosis is determined by immunohistochemistry, which is important for specific treatment. However, the typing of amyloidosis is not always straightforward due to various factors, e.g. the presence of other physiologically occurring structures (glycosaminoglycans, etc. Mass spectrometry is therefore used in addition to immunohistochemical methods. Genetic testing is also used in TTR amyloidosis to distinguish between familial and senile forms.

**AL amyloidosis** has a fairly specific pattern on ECG, unfortunately not always present. It is **low voltages in the limb leads, anterior wall infarct picture** and grade I AV block. Echocardiography usually reveals a size-normal to small left ventricle, ventricular wall hypertrophy and increased myocardial echogenicity due to extracellularly deposited amyloid. Because amyloidosis is a common cause of restrictive cardiomyopathy, **increased left**

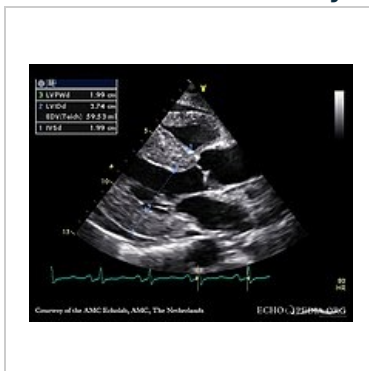**ventricular filling pressures** are also detected. The diagnosis includes cardiac magnetic resonance imaging. This reveals diffuse subendocardial late gadolinium enhancement (LGE) associated with changes in myocardial tissue in most cases.

In contrast to AL amyloidosis, voltages in the limb leads are often normal in **TTR amyloidosis**. Nonspecific conduction disturbances, ST-T segment changes and up to 50% atrial fibrillation are more likely to be present. There is also a higher incidence of left bundle branch block and higher grade AV block. The echocardiographic picture of TTR amyloidosis is similar to that of AL amyloidosis.

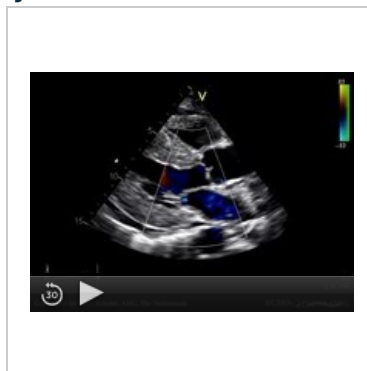### ECHO of artery amyloidosis



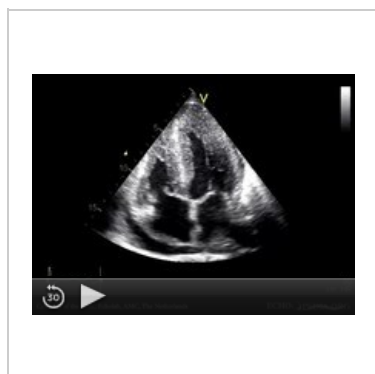
Restrictive cardiomyopathy with dilatation of both atria (4CH projection)



Cardiac amyloidosis with left ventricular wall hypertrophy and increased myocardial echogenicity (parasternal long axis projection)



Cardiac amyloidosis with left ventricular wall hypertrophy and increased myocardial echogenicity (parasternal long axis projection)



Cardiac amyloidosis with left ventricular wall hypertrophy and increased myocardial echogenicity (4CH projection)

## Treatment and prognosis

In cardiac amyloidosis, treatment is aimed at both **treating the heart failure** and **the actual cause of amyloid formation**. In AL amyloidosis, diuretics and aldosterone antagonists are primarily used in the treatment of heart failure. ACE inhibitors are often poorly tolerated (due to a combination of autonomic dysfunction and low cardiac output). In contrast, in TTR amyloidosis without autonomic neuropathy, low doses of ACE inhibitors are usually well tolerated. Due to the arrhythmic manifestations, a pacemaker is sometimes indicated.

Specific treatment of AL amyloidosis is **targeted to plasma cells, including the use of chemotherapeutic agents and specific monoclonal antibodies**. Reduction in serum light chain protein levels correlates with marked modification of heart failure manifestations. **Autologous stem cell transplantation** may also be considered, but has limitations.

In TTR amyloidosis, the transthyretin tetramer stabilizer **Tafamidis** is already beginning to be used in clinical practice. Other agents are under investigation. In both AL and TTR amyloidosis, heart transplantation is indicated in some cases. Without treatment, the prognosis of AL amyloidosis is least favourable, especially in patients with heart failure, where the survival time is less than 9 months.

## Resources

### Related Articles

- Cardiomyopathy
- Restrictive cardiomyopathy

## Used literature

- KAUTZNER, Josef. *Srdeční selhání : aktuality pro klinickou praxi*. - vydání. Mladá fronta, 2015. ISBN 9788020435736.
- MANN, Douglas L, et al. *Braunwald´s Heart Disease : A Textbook of Cardiovascular Medicine*. 10th Edition vydání. 2015. ISBN 978-0-323-29429-4.
- MUCHTAR, Eli, Lori A. BLAUWET a Morie A. GERTZ. Restrictive Cardiomyopathy. *Circulation Research*. 2017, roč. 7, vol. 121, s. 819-837, ISSN 0009-7330. DOI: 10.1161/circresaha.117.310982.
- PEREIRA, Naveen L., Martha GROGAN a G. William DEC. Spectrum of Restrictive and Infiltrative Cardiomyopathies. *Journal of the American College of Cardiology*. 2018, roč. 10, vol. 71, s. 1130-1148, ISSN 0735-1097. DOI: 10.1016/j.jacc.2018.01.016.
- PEREIRA, Naveen L., Martha GROGAN a G. William DEC. Spectrum of Restrictive and Infiltrative Cardiomyopathies. *Journal of the American College of Cardiology*. 2018, roč. 10, vol. 71, s. 1149-1166, ISSN 0735-1097. DOI: 10.1016/j.jacc.2018.01.017.
- STROUSE, Ch, et al. Approach to a patient with cardiac amyloidosis. *J Geriatr Cardiol*. 2019, roč. 16, vol. 7, s. 567-574,
- 

## References

1. MANN, Douglas L, et al. *Braunwald´s Heart Disease : A Textbook of Cardiovascular Medicine*. 10th Edition vydání. 2015. ISBN 978-0-323-29429-4.
2. MUCHTAR, Eli, Lori A. BLAUWET a Morie A. GERTZ. Restrictive Cardiomyopathy. *Circulation Research*. 2017, roč. 7, vol. 121, s. 819-837, ISSN 0009-7330. DOI: 10.1161/circresaha.117.310982.
3. PEREIRA, Naveen L., Martha GROGAN a G. William DEC. Spectrum of Restrictive and Infiltrative Cardiomyopathies. *Journal of the American College of Cardiology*. 2018, roč. 10, vol. 71, s. 1130-1148, ISSN 0735-1097. DOI: 10.1016/j.jacc.2018.01.016.
4. STROUSE, Ch, et al. Approach to a patient with cardiac amyloidosis. *J Geriatr Cardiol*. 2019, roč. 16, vol. 7, s. 567-574,