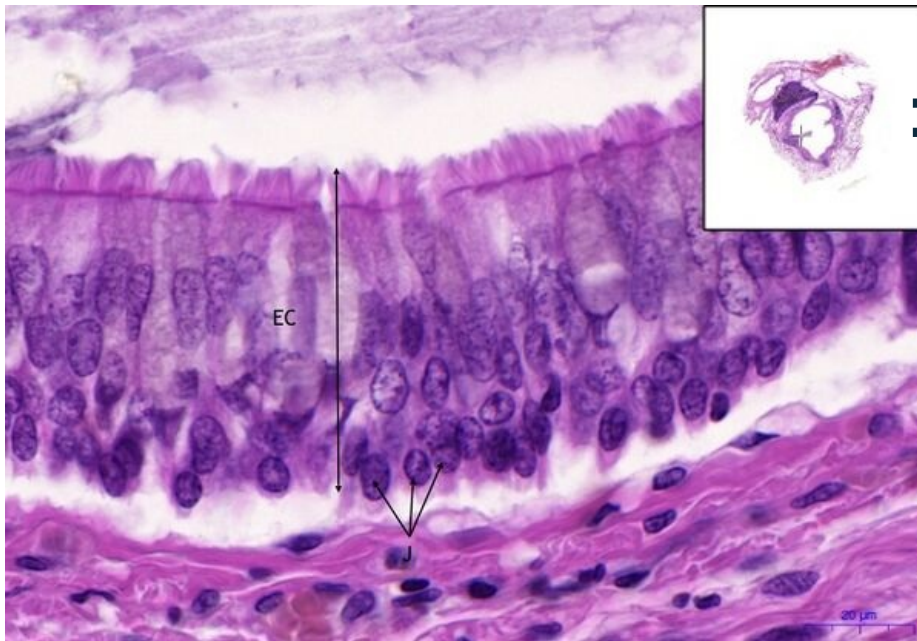


Bronchus HE

Bronchus - HE, 60,9x



Pseudostratified columnar epithelium with cilia:

- **EC** – columnar epithelium
- **J** – cell nucleus

Navigation: Epithelial tissue

← Preparation
no. 5

| List of
slides

| Preparation no. 7
→