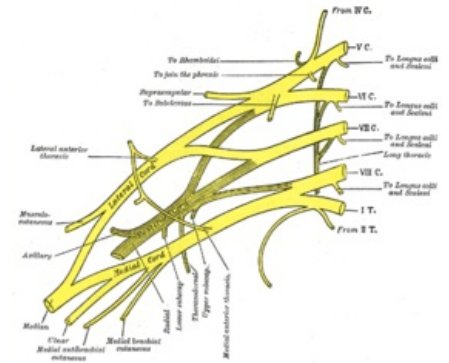


Brachial Plexus

The humerus knitting is formed by the connection of ventral branches C5–Th1, from C4 – weaker and variable coupling to C5. It extends from the outlets of the cervical spine through *the fissura scalenorum* to the axilla, connecting – 3 primary bundles – *trunci plexus brachialis*.

- **Truncus superior** - Superior trunk (C5 and C6 fibers).
- **Truncus medius** - Middle trunk (C7 fibers).
- **Truncus inferior** - Inferior trunk (fibers of C8 and Th1).

They descend further caudal and laterally behind the clavicle. Each bundle is divided into front and back branches. These reunite with each other to form 3 secondary bundles – *fasciculi plexus brachialis* – placed under *m. pectoralis minor* and encircling *a. axillaris*.



Scheme of the brachial plexus

Division based on the relationship to a. axillaris

- **Fasciculus lateralis (C5–C7)** – The lateral cord is formed by the connection of the anterior branches of *the truncus superior* and *medius*, laterally from *a. axillaris* – *n. musculocutaneus*, *radix lateralis nervi mediani* (lateral part of *n. medianus*).
- **Fasciculus medialis (C8–Th1)** – The medial cord separate anterior branch from *truncus inferior*, medially from *a. axillaris* – *radix medialis nervi mediani* (medial part *n. medianus*), *n. ulnaris*, *n. cutaneus brachii medialis* (weaker), *n. cutaneus antebrachii medialis*.
- **Fasciculus posterior s. dorsalis (C5–Th1)** – Deposited dorsally from *a. axillaris* – *n. axillaris*, *n. radialis*.

Branches of the Plexus Brachialis

Pars supraclavicularis

1. **Nervus dorsalis scapulae** (C5, C6) – Points to the medial edge of the scapula through *m. scalenus medius* a *posterior* and through *m. levator scapulae*, innervates: *mm. rhomboidei*, *m. levator scapulae*.
2. **Nervus thoracicus longus** (C5, C6) – Runs in the middle axillary line, after *m. serratus anterior* (innervates – paralysis is manifested by the impossibility of abduction of the arm above the horizontal).
3. **Nerve subclavius** (C5, C6) – Weak nerve directed under the clavicle, innervates: *m. subclavius* (in 20% stronger – conjunction with *n. phrenicus*).
4. **Nervus suprascapularis** (C4–C6) – Heads to the upper edge of the scapula along *the m. omohyoideus* and enters the *incisura scapulae* (under *the ligamentum transversum scapulae*) and the *fossa supra* and *infraspinata*, innervating: *m. supraspinatus*, *m. infraspinatus*, capsule of the shoulder joint.
5. **Nervus pectoralis medialis and lateralis** (C5–Th1) – Directed under the clavicle between the two pectoral muscles (innervating them).
6. **Nervus subscapularis** (C5–C7) – Several twigs, departing differently from *the plexus brachialis*, innervating: *m. subscapularis* and *m. teres major*.
7. **Nervus thoracodorsalis** (C6–C8) – Converges along the inner surface of *m. latissimus dorsi* to its lateral edge, innervates: *m. latissimus dorsi*.
8. **Rami musculares** – Short twigs – innervation: *mm. scaleni*, *m. longus colli*.

Pars infraclavicularis

1. **Nervus musculocutaneus** (C5–C7) – Separates in the axilla from *the fasciculus lateralis*, breaks through *m. coracobrachialis* (hence the old name of the muscle – *musculus perforatus Gasseri*) and enters between *m. biceps brachii* and *m. brachialis*, innervates: *m. coracobrachialis*, *m. biceps brachii*, *m. brachialis* – (motor flexors of the arm), continues on the forearm – *n. cutaneus antebrachii lateralis* (sensitive) – descends between *m. biceps* and *m. brachialis*, breaks through the fascia, joins the *vena cephalica antebrachii*, innervates: the skin of the lateral half of the forearm.
2. **Medianus nerve** (C5–Th1) – Formed by the connection of *radix medialis* and *radix lateralis*. Innervates majority of flexor muscles in the forearm, the thenar muscles, and the two lateral lumbricals. Sensory innervation to lateral part of the arm and lateral 3 and a half fingers of the palmar surface.
3. **Nervus ulnaris** (C8–Th1) – From *fasciculus medialis*. Innervates the hypothenar muscles of the hand and two medial lumbricals, flexor carpi ulnaris and medial half of flexor digitorum profundus. Sensory innervation to the medial one and a half fingers and palmar area.
4. **Nervus cutaneus brachii medialis** (C8–Th1) – A weak nerve from *the fasciculus medialis*, breaks through *the fascia axillaris* or up to the *fascia brachii* and enters the subcutaneous tissue, the final branch for the skin

of the medial half of the arm, during the *axilla of the junction* of the intercostal nerves (2, sometimes 3) – for the skin *of the axilla* – *nervi intercostobrachiales*.

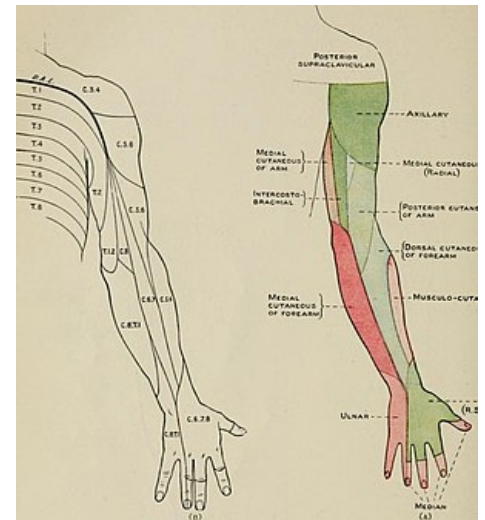
5. ***Nervus cutaneus antebrachii medialis*** (C8–Th1) – Weak nerve from *fasciculus medialis*, initially accompanied by *vena brachialis*, penetrating through *the hiatus basilicus* into the subcutaneous tissue, final branches for the skin on the ulnar side of the forearm – *ramus anterior* (radially from the vein, innervating: the front of the ulnar part of the forearm), *ramus ulnaris* (ulnar from the vein, turning to the dorsal side of the forearm).
6. ***Nervus axillaris*** (C5–C6) – innervates: *m. deltoideus* and *m. teres minor*, shoulder joint, *continues* – *nervus cutaneus brachii lateralis superior* into the subcutaneous tissue between *m. deltoideus* and *caput longum m. tricipitis brachii*, innervates: skin in the landscape of the deltoid muscle and skin of the lateral edge of the arm.
7. ***Nervus radialis*** (C5–C8, ev. Th1) – A strong nerve from *the fasciculus posterior*. Innervates the triceps brachii, and the extensors posterior compartment of the forearm .Sensory innervation to the arm and forearm posteriorly and the posterolateral aspect of the hand.

Links

Literature used

- PETROVICKÝ, Pavel. *Anatomie s topografií a klinickými aplikacemi*. 1. edition. Osveta, 2002. 542 pp. 3; ISBN 80-8063-048-8.

The Brachial Plexus - Sections - Branches - TeachMeAnatomy



innervation of arm