

Benign renal tumors

Benign renal tumors are rare. They include:

- **angiomyolipoma**,
- **hamartoma**,
- **fibroma**,
- **hemangioma**,
- **leiomyoma**,
- **adenoma** - 3 cm in diameter,
- **oncocytoma** (a type of adenoma that grows from the interstitial cells of the collecting ducts) - it has a round shape and doesn't metastasize. It is often asymptomatic. Histologically we are not able to differentiate an oncocytoma from a chromophobic renal carcinoma, therefore a nephrectomy is recommended.

Biologic behaviour of an adenoma + oncocytoma is unclear - nephrectomy is recommended.

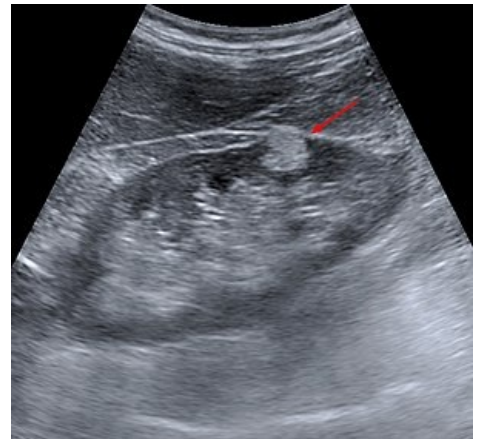
Links

Related articles

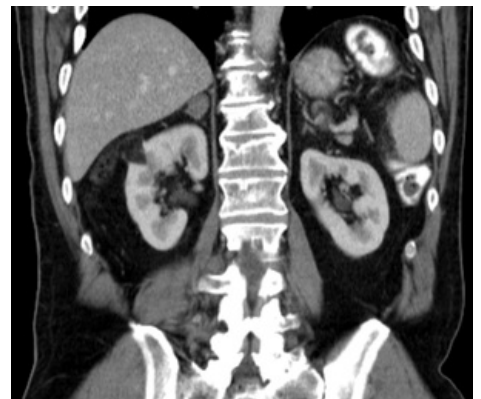- Kidney carcinoma
- Wilms tumor
- Kindney tumors

Sources

- KLENER, P, et al. *Vnitřní lékařství*. 3. edition. Praha : Galén, 2006. ISBN 80-7262-430-X.



Angiomyolipoma - ultrasound - hyperechogenic deposit /fat tissue/



Angiomyolipoma of the right kidney - CT - hypodense deposit /fat tissue/