

# Atlanto-occipital dislocation

**Atlantooccipital dislocation** (AOD) is a result of an *injury to the ligamentous complex connecting the atlas bone and the occipital bone of the head.*

According to the **clinical picture**, we divide patients into 2 groups:

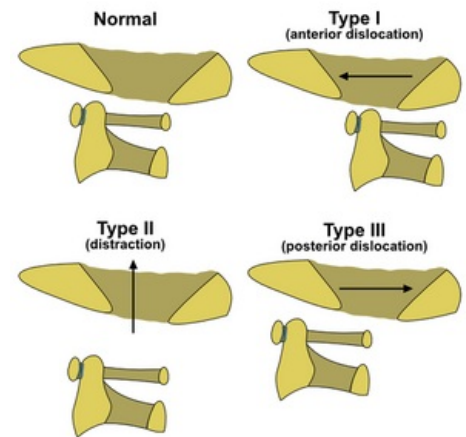
1. Without a significant neurological lesion (CAVE: overlooked injury),
2. With a severe deficit and impaired vital functions.

The **graphic examination** consists of:

- X-ray of the craniocervical junction in the transoral projection and the lateral projection (standard anteroposterior CC does not show the transition due to summation with the lower jaw), \* CT, or MRI.

**Therapy:** A fundamental contraindication is a traction in the longitudinal direction!

- The surgical solution includes occipitocervical fusion through a posterior approach and then 3 months of fixation in a Philadelphia collar (general rule after a surgical solution of cervical spine injuries),
- A conservative option is several months of immobilization in a light vest.



Types of atlanto-occipital dislocations

## Links

### External links

- Mefanet: <http://mefanet.lfp.cuni.cz/clanky.php?aid=328>, Poranění páteře
- PubMed: Atlanto-occipital dislocation (<https://www.ncbi.nlm.nih.gov/pmc/articles/PMC4363805/>)

## References

- SAMEŠ, M, et al. *Neurochirurgie*. 1. edition. Praha : Jessenius Maxdorf, 2005. ISBN 80-7345-072-0.