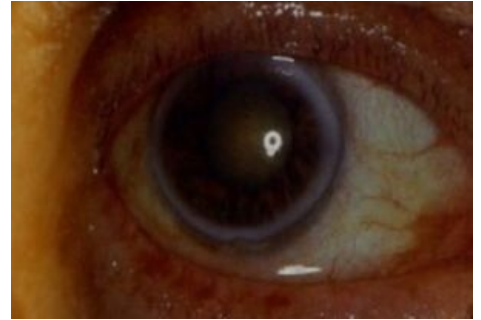


Arcus Senilis Corneae

Gray-white ring of corneal lipid deposits in limbus of the eye . Usually **double-sided**. It arises **at the age of over 60**. Its outer perimeter is sharply demarcated as opposed to the less sharply demarcated inner perimeter. Lipid deposits diffuse from the limbal vessels. When created **before the age of 50**, we look for metabolic disorders of lipids (hypercholesterolemia) = **arcus lipoides corneae**. It does not affect visual acuity.



Links

Related articles

- Eye as an optical system
- Corneal deposits
- Corneal degeneration and dystrophy

References

-
-

ROZSÍVAL, Pavel, et al. *Ophthalmology*. 1st edition. Galén, Karolinum, 2006. 373 pp. ISBN 80-7262-404-0 .

VOKURKA, Martin and Jan HUGO, et al. *Great medical dictionary*. 7th edition. Prague: Maxdorf, 2007. 1084 pp. ISBN 978-80-7345-130-1 .