


Aorta (histological slide)

Overview



Preparation no.1



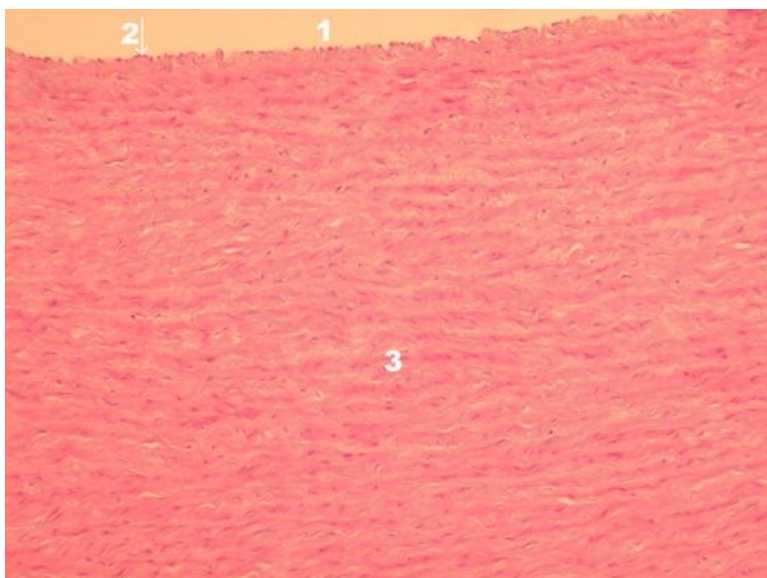
Name: **Aorta - Example of an Elastic Type Artery - Overview (HE)**

Description: 1 - aortic lumen, 2 - endothelium, 3 - vasa vasorum in tunica adventitia, i - tunica intima, m - tunica media,

and - tunica adventitia, in elastic-type arteries, the membrana elastica interna is hardly distinguishable from elastic ones

membranes in the middle layer

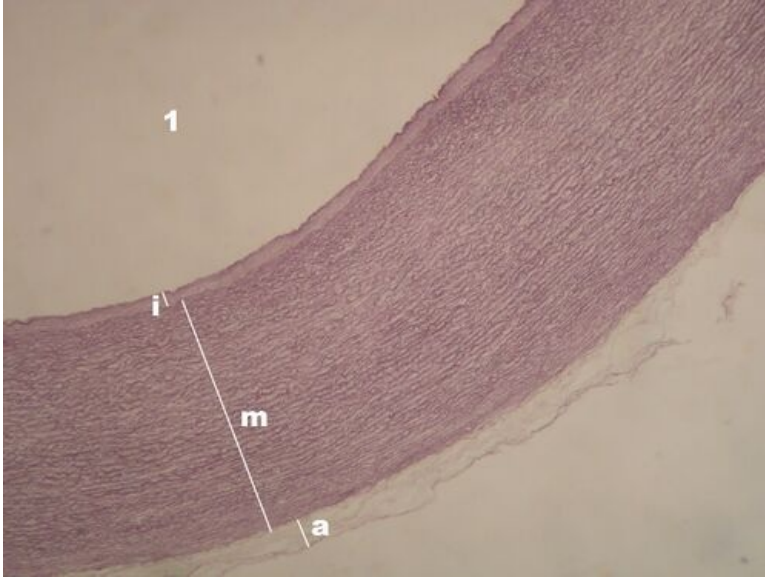
Preparation no. 2



Name: **Aorta - tunica media detail (HE)**

Description: 1 – aortic lumen, 2 – endothelium, 3 – tunica media

Preparation no. 3

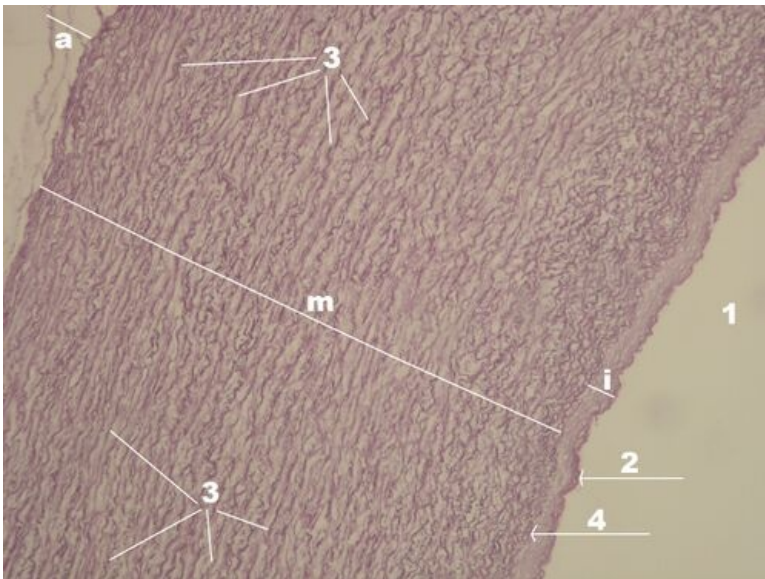


Name: **Aorta - overview (resorcin-fuchsin)**

Description: 1 – aortic lumen, i – tunica intima, m – tunica media, a – tunica adventitia

note: resorcin-fuchsin is a stain for elastic fibers

Preparation no. 4

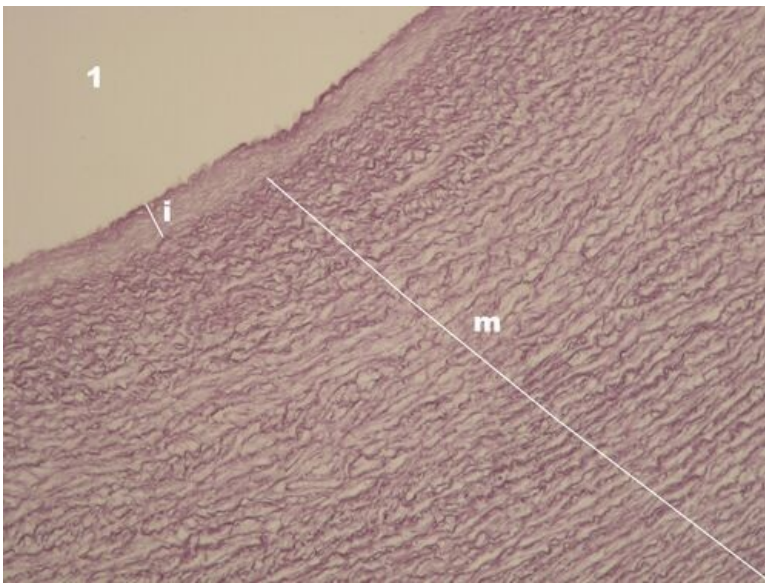


Name: **Aorta - wall layers (resorcin-fuchsin)**

Description: 1 – aortic lumen, 2 – endothelium, 3 – elastic membranes in the middle layer, 4 – the first of the elastic membranes (=membrana elastica interna), i – tunica intima, m – tunica media, and – tunica adventitia

note: resorcin-fuchsin is a stain for elastic fibers

Preparation no. 5



Name: **Aorta - tunica media detail (resorcin-fuchsin)**

Description: 1 – aortic lumen, i – tunica intima, m – tunica media

note: resorcin-fuchsin is a stain for elastic fibers

Connective tissue

Mesenchyme (preparation)

Umbilical cord (preparation)

Aorta (preparation)

Brown adipose tissue (preparation)

Adipose tissue (histology slide)

Tendon (preparation)

Articular cartilage (preparation)

Epiglottis (preparation)

Desmogenous ossification (preparation)

Enchondral ossification (preparation)

Lamellar bone (preparation)

Links

- Module Cellular Basics of medicine(3. LF UK)

Study materials

- Aorta