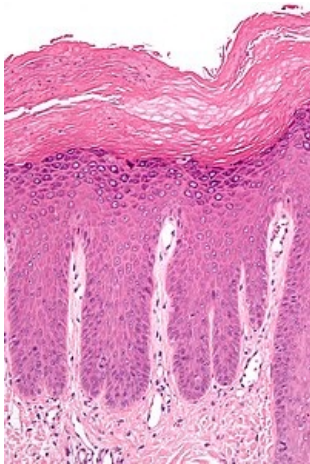


# Acanthosis

## Characteristics

Expansion of the epidermis due to proliferation of stratum spinosum cells <sup>[1]</sup> It can occur as a reaction to chronic irritation - inflammatory processes, tumors.

It is among the histopathological findings in lichen ruber planus.



Hyperkeratosis (above) and **acanthosis** (below) in lichen simplex chronicus

## Links

### Related articles

- Histopathological changes in the skin
- Skin

### References

- POVÝŠIL, Ctibor. *Speciální patologie*. 2. edition. Galén, 2007. 430 pp. ISBN 978-807262-494-2.
- ŠTORK, Jiří. *Dermatovenerologie*. 1. edition. Galén, Karolinum, 2008. 0 pp. ISBN 978-80-7262-371-6.

### Reference

1. VOKURKA, Martin and Jan HUGO, et al. *The Great Medical Dictionary*. 8th edition. Prague: Maxdorf, 2009. 1144 pp. ISBN 978-80-7345-166-0 .