

Muscular Lacuna

English: *Muscular lacuna*

Latin: *Lacuna musculorum*



Muscular lacuna' (Latin: *Lacuna musculorum*) is an anatomical structure placed behind/bellow the inguinal ligament. Lacuna vasorum is medially, while lacuna musculorum is laterally.

Contents of lacuna musculorum:

- Femoral nerve
- Iliopsoas
- Lateral femoral cutaneous nerve

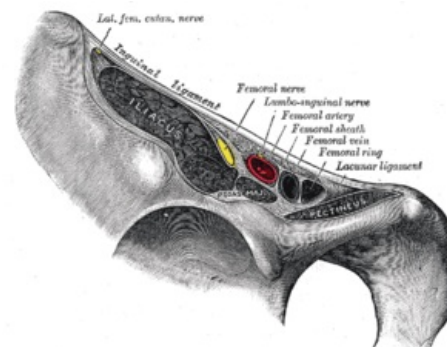
Links

Related articles

- Vascular Lacuna

Bibliography

- PETROVICKY, Pavel, et al. *Anatomie s topografií a klinickými aplikacemi : Sv. 1, Pohybové ústrojí. 1.* edition. Martin : Osveta, 2001. 463 pp. ISBN 80-8063-046-1.



Lacuna musculorum and lacuna vasorum