

Category:Pathology

Pages in category "Pathology"

The following 200 pages are in this category, out of 839 total.

(previous page) (next page)

A

- Abdominal Pain
- Abrasion (Dentistry)
- Abscess
- Acanthosis
- Achalasia
- Acquired coagulopathies
- Acquired heart defects
- Actinomyces israeli
- Actinomycosis
- Acute autoimmune thrombocytopenic purpura
- Acute bronchitis
- Acute immune thrombocytopenic purpura
- Acute inflammation
- Acute intermittent porphyria
- Acute Laryngitis
- Acute lymphoblastic leukemia
- Acute Lymphoblastic Leukemia
- Acute myeloid leukemia
- Acute myleoid leukemia
- Acute necrosis of pancreas
- Acute obstructive laryngitis
- Acute osteomyelitis
- Acute pancreatic necrosis
- Acute Pancreatitis
- Acute pancreatitis (diagnostic tests)
- Acute pharyngitis
- Acute phase reactants
- Acute respiratory distress syndrome
- Adaptation of tissues and organs
- Addison's disease
- Adenoameloblastoma
- Adnexitis
- Adrenal glands
- Agents of cardiovascular infections
- Akantosis
- Albers-Schönberg Disease
- Albinism
- Allergic contact dermatitis
- Allergic professional diseases of the airways and lungs
- Allergy
- Alport's syndrome
- Ameloblastic fibroma
- Ameloblastic Fibroma
- Ameloblastoma
- Anaemia
- Anaphylactic shock
- Anaphylaxis
- Anaplastic thyroid cancer
- Anemia from decreased erythrocyte production
- Anemia from reduced erythrocyte production
- Anemia of chronic disease
- Anemia of chronic diseases
- Aneurysm
- Angina pectoris
- Angler pneumoconiosis
- Anitschkow (Anichkov) cells
- Ankylosing spondylarthritis
- Anthracosis
- Antitrypsin deficiency
- Aortic stenosis
- Apoptosis

- Apoptosis
- Apoptosis and clinical consequences of its dysregulation
- Apoptosis signaling disorders in tumor cells
- Arachnoid cysts
- Arrhythmias (pediatrics)
- Arrhythmogenic cardiomyopathy
- Arteriosclerosis
- Arthritis uratica (gout)
- Arthrogryposis multiplex congenita
- Asbestos
- Asbestos disease
- Asbestos-related diseases
- Asbestosis
- Asbestosis (lung disease)
- Aschoff cells
- Ascites
- Asphyxia
- Asthma
- Atelectasis
- Atopic eczema
- Atrial Fibrillation
- Atrial septal defect
- Atrophy
- Atrophy - pathology
- Attrition
- Atypical pneumonia
- Autoimmune Diseases
- Autoimmune diseases
- Autoimmune liver disease
- Autoimmune pancreatitis
- Autopsy protocol (pathology)
- Autosomally inherited agammaglobulinemia
- Avascular bone necrosis
- Azotemia

B

- Bacteremia
- Bacterial Endocarditis (histological slide)
- Bacterial meningitis (infection)
- Bacterial meningitis (paediatrics)
- Bajliom
- Balzer's necrosis
- Bannayan-Riley-Ruvalcaba syndrome
- Barrett's Esophagus
- Bartter syndrome
- Basal cell carcinoma/PGS
- Basalioma
- Bence-Jones protein
- Benign
- Benign kidney tumors
- Benign prostatic hyperplasia
- Benign renal tumors
- Benign salivary gland tumors
- Biliary tract
- Biological characteristics of tumors
- Biological properties of tumors
- Biology of tumor growth
- Biopsy
- Blackfan Diamond Anemia
- Bladder Cancer
- Bladder carcinoma
- Bleeding
- Botulism (C. Botulinum)
- Bowel malrotation and volvulus
- Bowen's disease
- Brain abscess
- Brain contusions and lacerations
- Talk:Brain edema
- Brain edema
- Brain herniation
- BRCA
- Breast cancer in a man
- Breast Tumors
- Breast tumours
- Brenner tumor

- Brenner tumor
- Bronchiectasis (1.LF)
- Bronchiolitis
- Bronchogenic carcinoma
- Bruton's agammaglobulinemia
- Budd - Chiari syndrome
- Budd-Chiari Syndrome
- Burkitt lymphoma

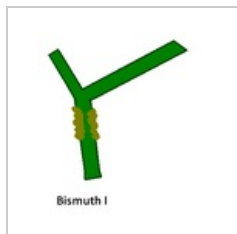
C

- Calcification of the dental pulp
- Calculi
- Cancer Cells Characteristics
- Cancer of the bladder
- Candidosis
- Carbuncle
- Carcinogenicity of Substances and Factors in the Environment
- Carcinogens
- Carcinoid
- Carcinoma
- Cardiac Amyloidosis
- Cardiac sarcoidosis
- Cardiogenic shock (CS)
- Cardiomegaly
- Cardiomyopathies
- Cardiomyopathy (CM)
- Cardiovascular disease in the elderly
- Carotid artery dissection
- Caudae equinae tumors
- Caudal tumors
- Causes of circulatory insufficiency in the heart
- Celiac disease
- Cell
- Cementoblastoma
- Cementoma
- Cerebral ischemia
- Cerebrovascular Event (Stroke)
- Cervical cancer
- Charcot-Marie-Tooth Syndrome
- Cherry stain
- Cherry-red spot
- Cherubism
- Cholesteatoma
- Chondroma
- Chondrosarcoma
- Chronic bronchitis
- Chronic inflammation
- Chronic leukemia (guide)
- Chronic nerve compression syndromes (entrapment), peripheral nerve tumors
- Chronic Pancreatitis
- Chronic subdural hematoma
- Churg-Strauss syndrome
- Circulating tumor cells
- Circulatory collapse
- Classification of pneumonias (pathology)
- Coal worker's pneumoconiosis
- Cold injury
- Collection of material for histological examination
- Colon polyps
- Colorectal adenoma
- Colorectal cancer
- Colorectal cancer/pathology
- Colorectal cancer/PGS
- Colorectal carcinoma
- Colorectal carcinoma (PGS)
- Community-acquired pneumonia
- Complications of diabetes mellitus
- Complications of gastric and duodenal ulcers
- Concretions
- Concussion

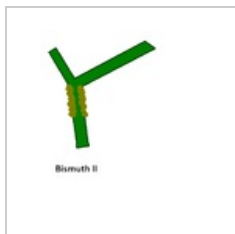
(previous page) (next page)

Media in category "Pathology"

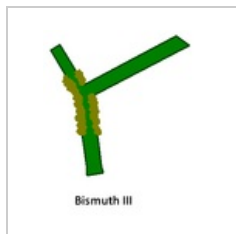
The following 12 files are in this category, out of 12 total.



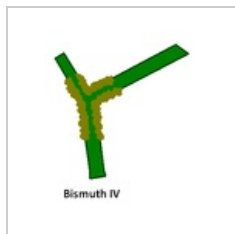
Bismuth I.PNG
320 × 343; 5 KB



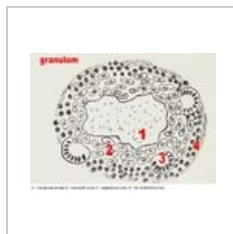Bismuth II.PNG
398 × 446; 7 KB



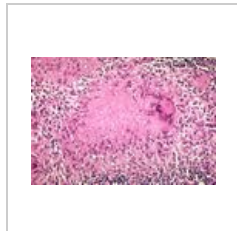
Bismuth III.PNG
296 × 341; 5 KB



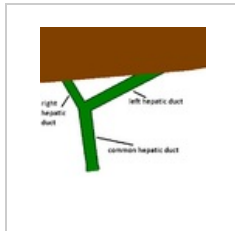
Bismuth IV.PNG
302 × 355; 6 KB



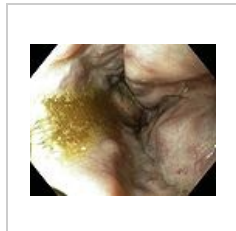
Granulom.jpg
615 × 464; 62 KB



Granuloma necro...
600 × 413; 112 KB



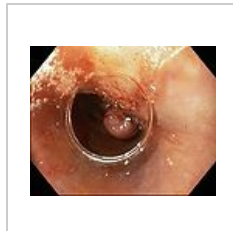
Hepatiky s játry....
398 × 446; 8 KB




Ligace2.JPG
643 × 527; 39 KB



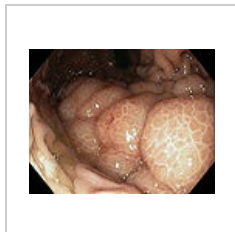Ligace3.JPG
645 × 524; 53 KB



Ligace5.JPG
644 × 523; 45 KB



Patologie.png
50 × 50; 4 KB



Žal-varixy.jpg
510 × 400; 170 KB