

Category:Paediatrics

Pages in category "Paediatrics"

The following 200 pages are in this category, out of 659 total.

(previous page) (next page)

A

- A child at risk, endangered child
- A hyperkinetic child
- A sign of the setting sun
- Abdominal pain (pediatrics)
- Abdominal Pain in Children (Paediatrics)
- Abdominal paracentesis (pediatrics)
- Abdominal puncture (paediatrics)
- Abscessive pneumonia
- Absentee pneumonia
- Acid-base balance disorders (neonatology)
- Acid-Base Disorders (Neonatology)
- Acne vulgaris
- Acute abdomen in children
- Acute appendicitis
- Acute bronchitis
- Acute epiglottitis
- Acute Glomerulonephritis
- Acute inflammations of larynx
- Acute lymphoblastic leukemia
- Acute osteomyelitis
- Acute otitis media
- Acute pharyngitis
- Addison's disease
- Adenoid vegetations
- Adnate HSV infection
- Adolescence
- Adolescent risk behavior syndrome
- Adrenal crisis
- Amniocentesis
- An Infant
- Anaphylaxis
- Anesthesia (pediatrics)
- Angelman Syndrome
- Angelman syndrome (genetics)
- Angina
- Angina fever
- Anorexia Nervosa
- Antibiotics (neonatology)
- Antipsychotics (pediatrics)
- Aortic regurgitation
- Aortic stenosis
- Apert syndrome
- Apgar score
- Aplasia fibulae congenita
- Aplasia radii congenita
- Apnea (newborn)
- Appendicitis (pediatrics)
- Arachnodactyly
- Arthrogryposis multiplex congenita
- Artificial nutrition of the infant
- Artificial pulmonary ventilation (neonatology)
- Aspiration of a foreign body
- Asthma
- Atopic eczema
- Atresia and stenoses of the small intestine
- Atrial septal defect
- Atypical pneumonia
- Autoimmune liver diseases
- Autoregulation of cerebral perfusion
- Autosomal inherited agammaglobulinemia
- Avascular bone necrosis

- Avascular bone necrosis

B

- Baby massages
- Bacterial Gastroenteritis
- Bacterial meningitis (paediatrics)
- Bacterial tracheitis
- Bannayan-Riley-Ruvalcaba syndrome
- Bartter syndrome
- Basic tests in hematology (pediatrics)
- Beckwith - Wiedemann Syndrome
- Beckwith-Wiedemann Syndrome
- Behavioral Disorders (Paediatrics)
- Benzodiazepines (peditarics)
- Bicuspid Aortic Valve
- Birth Trauma
- Birth traumatism
- Bladder Catheterization (Pediatrics)
- Bleeding conditions (pediatrics)
- Bleeding from the alimentary canal
- Bloch-Sulzberg syndrome
- Blood in the stool of a newborn
- Bone age
- Bowel emptying disorders
- Bowel malrotation and volvulus
- Brain perfusion autoregulation
- Brain ultrasonography (neonatology)
- Brainstem potentials
- Breast Feeding
- Breastfeeding
- Bronchiectasis (1.LF)
- Bronchiolitis
- Brown fat
- Bruton's agammaglobulinemia
- Burn Injury

C

- Calcium phosphate metabolism
- Campylobacter Enteritis
- Campylobacter enteritis 1.If
- Caput succedaneum
- Cardiac inflammations (pediatrics)
- Cardiac tamponade (pediatrics)
- Cardiac tamponade (pediatry)
- Cardiogenic shock (pediatrics)
- Cardiomyopathies
- Cardiomyopathy (CM)
- Cardiopulmonary monitoring
- Cardiopulmonary resuscitation (pediatrics)
- Caring for a child with Down syndrome
- Catheterization of the bladder
- Central cyanosis
- Central palsy
- Central paralysis
- Central vein cannulation (pediatrics)
- Cephalhematoma
- Cerebral Palsy in Children
- Cerebral-induced salt loss syndrome
- Chickenpox
- Child age distribution
- Child growth and development
- Child nutrition
- Children's cerebral palsy
- Children's neuroses
- Children's sandpit
- Chronic eating disorders
- Chronic Glomerulonephritis
- Chronic Granulomatous Disease
- Chronic kidney disease
- Chronic Otitis Media
- Chronic renal dysfunction (pediatrics)
- Chronic subdural hematoma
- Classification of shock (pediatrics)

- Cleft defect
- Clinical signs of shock (pediatrics)
- Clubfoot (congenital talipes equinovarus)
- Coarctation of the aorta
- Congenita muscularis torticollis
- Congenital adrenal hyperplasia
- Congenital cataract
- Congenital chylothorax
- Congenital defects of metabolism with acute symptomatology
- Congenital defects of the external and middle ear
- Congenital defects of the gastrointestinal tract
- Congenital defects of the inner ear
- Congenital defects of the nervous system
- Congenital defects of the urinary system
- Congenital deformities of the auricle
- Congenital deformities of the neck
- Congenital developmental defects
- Congenital developmental defects of the newborn requiring an urgent solution
- Congenital developmental defects of the respiratory system
- Congenital diaphragmatic hernia
- Congenital disorders of glycosylation
- Congenital disorders of phenylalanine metabolism
- Congenital glycosylation disorders
- Congenital Heart Defects
- Congenital hypertrophic pyloric stenosis
- Congenital hypothyroidism
- Congenital laryngeal stridor
- Congenital malformations of the auricle
- Congenital malformations of the respiratory system
- Congenital Megacolon
- Congenital multiple exostoses
- Congenital steep talus
- Congenital syphilis
- Congenital thrombophilia
- Congenital toxoplasmosis
- Conglutination
- Connection to the skull
- Consciousness and its disorders
- Constipation (Pediatrics)
- Constrictive pericarditis
- Convulsions (pediatrics)
- Cough (pediatrics)
- Cow's milk protein allergy
- Coxa vara adolescentium
- Credeisation
- Credification
- Cri du chat syndrome
- Crigler-Najjar syndrome
- Crossed movement patterns in movement development
- Cushing's syndrome
- Cyanosis (neonatology)
- Cystic Fibrosis
- Cystic fibrosis

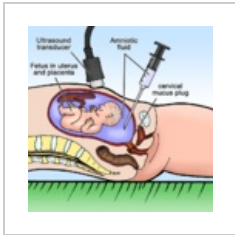
D

- Dandy-Walker syndrome
- DeLange syndrome
- Delayed puberty (puberta tarda)
- Dental caries in childhood
- Dermatomycoses
- Dermatomycosis
- Development of teeth
- Developmental defects of the body wall
- Developmental disorders of the ear
- Developmental hip dysplasia
- Diabetes mellitus (pediatric)
- Diabetic ketoacidosis
- Diaphragmatic hernia
- Diarrhea
- Diarrhea (pediatrics)
- Diarrheal diseases (guide)
- Diarrheal diseases (signpost)
- Diastrophic dwarfism

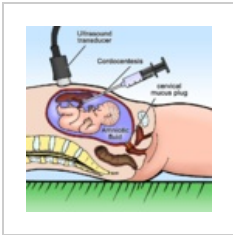
(previous page) (next page)

Media in category "Paediatrics"

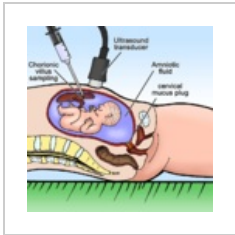
The following 3 files are in this category, out of 3 total.



Amniocentesis.png
800 × 800; 122 KB



Cordocentesis.png
800 × 800; 114 KB



Villus sampling.png
800 × 800; 118 KB