

Category:Neurosurgery

Pages in category "Neurosurgery"

The following 134 pages are in this category, out of 134 total.

A

- Apert syndrome
- Arachnoid cysts
- Arteriovenous malformations
- Astrocytoma
- Atlanto-occipital dislocation
- Atlas injury (C1)
- Axis injury

B

- Bacterial meningitis (infection)
- Bleeding into the brain parenchyma
- Bleeding into the capsula interna
- Brachial plexus paresis
- Brain abscess
- Brain contusions and lacerations
- Talk:Brain edema
- Brain edema
- Brain gliomas
- Brain herniation
- Brudzinski's sign

C

- Carotid endarterectomy
- Carpal tunnel syndrome
- Carrier Injury (C1)
- Caudae equinae tumors
- Caudal tumors
- Cavernous sinus
- Central nervous system
- Cerebral ischemia
- Cervical plexus
- Chiari malformation
- Chronic compression syndromes (entrapment) of nerves, tumors of peripheral nerves
- Chronic subdural hematoma
- Chvostek Sign
- Cone (C2) injury
- Cone syndrome
- Congenital defects of the nervous system
- Craniocerebral and spinal trauma
- Craniopharyngioma
- Craniostenosis
- Cubital tunnel syndrome

D

- Dandy-Walker syndrome
- Decerebrate rigidity
- Decorticate rigidity
- Deep Brain Stimulation
- Degenerative diseases of the cervical spine

E

- Electrophysiological methods in clinical diagnosis
- Ependymom (pathology)
- Ependymoma
- Ependymoma (pathology)
- Epicon syndrome
- Epidural hematoma

- Epidural Hematoma
- Epileptic Lesion
- Extra-intracranial anastomosis

F

- Facial hemispasm
- Flatau's sign

G

- Gamma knife
- Glioblastoma multiforme
- Gliomas of the brain
- Glossopharyngeal neuralgia
- Griesinger's flag
- Guyon's canal syndrome

H

- Hemiplegia
- Hemiplegia alternans
- Hemodynamic swelling of the brain
- Hemorrhagic strokes
- Hydrocephalus

I

- Idiopathic intracranial hypertension
- Inflammatory intracranial diseases
- Injury
- Internal capsule
- Interventional Radiology
- Intracranial hypertension
- Intracranial Metastases

L

- Lasegue's sign
- Lhermitt sign
- Lumbar puncture
- Lumbar spinal canal stenosis

M

- Meningioma
- Meningiomas
- Meningocele
- Meralgia paresthetica
- Mononeuritis multiplex

N

- Nausea
- Nerve injuries of the upper limb
- Nerve root syndrome
- Portal:Neurosurgery
- Normotensive hydrocephalus
- Nuchal rigidity

O

- Occupational peripheral nerve damage
- Of cerebrospinal fluid
- Oligodendroglioma
- Osteomyelitis cranii

P

- Parietal lobe syndrome
- Peripheral nerve injury
- Peripheral Palsy
- Peripheral palsy

- Phalen's test
- Plexus cervicalis
- Post commotio syndrome
- Posttraumatic facial nerve palsy
- Prefrontal syndrome
- Prevention of secondary damage to the spinal cord, indications for urgent surgery in terms of spinal cord decompression
- Prolactinoma

R

- Rolandic syndrome
- Root syndroms
- Rossolimo phenomenon

S

- Scheuermann's disease
- Skull fractures
- Spinal tumors
- Spine sign
- Spondylolisthesis
- Spontaneous intracerebral hemorrhage in hypertensive patients
- Stereotaxis
- Subdural hematoma
- Suppurative meningitis (infection)
- Surgical approaches to the brain and spinal cord
- Surgical treatment of epilepsy
- Surgical treatment of pain
- Surgical treatment of Parkinson's disease
- Symptom of neck opposition
- Syndroma caudae equinae
- Syndromes of chronic compression (entrapment) of nerves, tumors of peripheral nerves
- Syringomyelia

T


- Tails' sign
- The sign of opposition is the isthmus
- Time distribution of neurosurgical operations
- Traumatic spinal cord syndromes
- Tripod (Amoss) sign
- Trousseau's sign
- Tumors of cerebellum and IV. ventricle in adults
- Tumors of peripheral nerves
- Tumors of the cauda
- Tumors of the cerebellum and IV. ventricles in adults

V

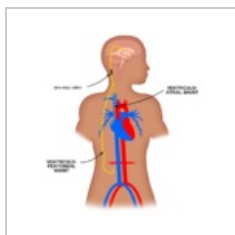
- Vestibular Schwannoma
- Von Hippel-Lindau syndrome

Media in category "Neurosurgery"

The following 2 files are in this category, out of 2 total.



Neurochirurgie.png
50 × 50; 5 KB



VP-VA Shunt en.p...
1,024 × 1,024; 69 KB