

Budd-Chiari Syndrome

Budd-Chiari syndrome is **hepatic veins occlusion**. The consequences are portal hypertension because of blood congestion in liver and portal venous system and finally liver cirrhosis and failure. This syndrome is **quite infrequent**.^[1]

Note: hepatic veins bring the blood from liver to inferior vena cava (see picture).

Signs and Symptoms

The acute signs of the syndrome may include: severe abdominal pain, jaundice, hepatomegaly, ascites and other symptoms associated with liver problems. Most patients have a slower onset^[2] and it was discovered accidentally they may be symptom-free and or may already have progressive cirrhosis and liver failure.

Pathophysiology and etiology

The most common cause is **hepatic veins thrombosis** (75%)^[2] in patients with primary predisposition (coagulopathies like Protein C or Protein S deficiency, Leiden mutation...) or other factors like:

- polycythemia vera;
- use of oral contraceptives;
- trauma (cause of a new abnormality of hepatic vein);
- pregnancy.

Other causes of hepatic veins occlusion (25%)^[2] can be:

- hepatocellular carcinoma;
- metastasis in liver;
- infections in liver (TB).

Diagnostic

There are a few diagnostic methods for hepatic veins examination:

- **USG** of liver with Doppler;
- **CT**, CT angiography;

Other methods:

- **lab**: elevated liver markers (AST, ALT), possible coagulopathy;
- hematology: RBC abnormalities, thrombocytopenia...

But there is usually portal hypertension symptoms domination (ascites, esophageal varices). That is the reason, why Budd-Chari syndrome should be always excluded in patients with portal hypertension and liver cirrhosis!

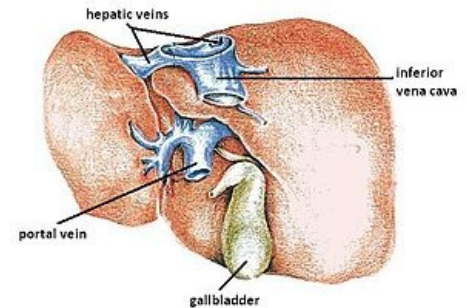
Complications

- portal hypertension (with all consequences);
- nonalcoholic liver cirrhosis and failure;
- pulmonary embolism.

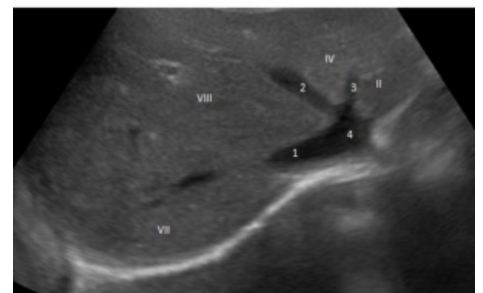
Therapy

- **therapy of the cause**:
 - thrombophilia (heparin, warfarin);
- **therapy of consequences**:
 - therapy of portal hypertension;
 - liver transplantation.

Links



Liver and localization of hepatic veins.



Liver, hepatic veins (1, 2, and 3) and inferior vena cava (4) in USG.

Related articles

- Cirrhosis
- Portal Hypertension
- Ascites

References

1. KASPER, Dennis L – FAUCI, Anthony S – LONGO, Dan L, et al. *Harrison's principles of Internal Medicine*. 16th edition. New York : McGraw-Hill Companies, Inc, 2005. 2607 pp. pp. 1892-1896. ISBN 0-07-139140-1.
2. Wikipedia.org. *Budd–Chiari syndrome* [online]. Wikipedia.org, ©2011. The last revision 2011-08-13, [cit. 2011-09-19]. <http://en.wikipedia.org/wiki/Budd-Chiari_syndrome>.