

# Urethra

The **urethra** is a part of the lower urinary tract. In men it is also part of the genital tract. Its function is to remove the urine from the body, in men also to ejaculate.

## Urethra feminina

The female urethra is only part of the urinary tract. It is 3-4 cm long. The urethra begins as the **ostium urethrae internum** in the urinary bladder wall and opens as the **ostium urethrae externum** on the *papilla urethralis*. The bladder opening is divided into two parts - ostium urethrae internum accipiens (the part that is a continuation of the cervix vesicae) and ostium urethrae internum evacuans (the part whose wall is contracted and relaxes during urination).

### Parts of the urethra

The urethra is divided into three parts:

- **Pars intramuralis** – passes through the wall of the bladder
- **Pars pelvica** – the section between the urinary bladder and the urogenital diaphragm
- **Pars perinealis** – part from the urogenital diaphragm to the external opening

### Wall construction

The **mucous membrane** is covered with transitional epithelium, which in the lower third is gradually replaced by stratified squamous epithelium without cornification. The mucous membrane is folded into cilia, between which there are pits, *lacunae urethrales*, into which small mucus-producing glands open. Thanks to the cilia, the female urethra has a star-shaped cross-section, but in the perineal section it has the shape of a longitudinal slit. The mucosal tissue is high and contains venous plexuses that shine through and form a reddish-purple coloration of the mucosa. The venous plexus participates in clamping the tube, this layer is therefore referred to as the **tunica spongiosa**.

The **muscle** part of the wall has two sub-parts – an inner layer (made of smooth muscle) and an outer layer (made of striated muscle). Smooth muscle has a predominantly longitudinal course, mostly in the inner layer of the tube. The external circular layer of smooth muscle forms the **m. sphincter urethrae internus** in the central part of the urethra, around which is a sphincter made of striated muscle, the **m. sphincter urethrae externus**.

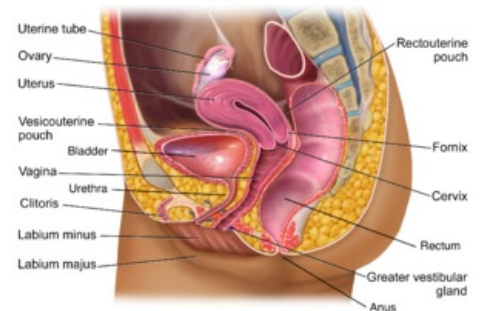
The **fibrous surface** is referred to as the paraurethrium.

## Urethra masculina

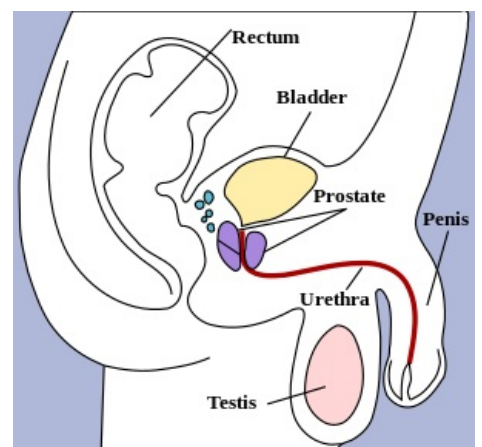
A man's urethra is simultaneously a urinary and sexual outlet (from the opening of the ductus ejaculatorii). It is 20-22 cm long. It begins as the **ostium urethrae internum** in the bladder wall and opens as the **ostium urethrae externum** on the glans penis.

### Parts of the urethra

- **Pars intramuralis** (0.5 cm) – passes through the wall of the bladder. From the wall continues a smooth muscle part as the **m. sphincter vesicae**.
- **Pars prostatica** (3-4 cm) – runs through the prostate. On the posterior side, the **colliculus seminalis** projects into the tube. The ductus ejaculatorii opens on its sides and the utricle prostaticus on its top. Next to the sides of the colliculi seminales, the ductuli prostatici (the outlets of the prostate glands) open into the grooves. By colliculus seminalis, the cross-section of the tube is crescent-shaped. The urethra is slightly dilated here.
- **Pars membranacea** (2 cm) – is part of the tube passing through the urogenital diaphragm. This is the narrowest section of the tube. In this part it has a star-shaped cross-section. At the junction of pars membranacea and pars spongiosa, bulbourethral glands open.
- **Pars spongiosa** (15 cm) – runs in the corpus spongiosum of the penis. Just before the external orifice, the urethra expands longitudinally in the **fossa navicularis urethrae**. The cross-section of the tube in the pars spongiosa has a shape of a transverse slit, in the osium urethrae externum it has a shape of a vertical slit.



The inner female reproductive organs



Male urethra drawn in red

### Curvatures of the urethra

- **Curvatura subpubica** – curvature at the beginning of pars spongiosa, which is extended in the ampulla urethrae. Here the urethra changes its course from vertical and continues forward and slightly upwards. This curvature is fixed.
- **Prepubic curvature** – changes the direction of the course back to vertical. It is straightened when the penis is erect, it can also be leveled when the catheter is inserted.

#### Wall construction

- **Mucous membrane** - the color of the mucous membrane is pink. It is folded into longitudinal cilia and contains lacunae urethrales, into which the mucus glands open (similar to the female urethra). In the upper half of the prostatic part, the tube has a transitional epithelium, then the multi-row cylindrical epithelium continues up to the fossa navicularis, where it is replaced by a stratified squamous epithelium without cornification.
- **The muscle** – smooth muscle has an inner longitudinal and an outer circular part. In the intramural section, the circular part is formed with the sphincter - **m. sphincter urethrae internus**. Around this sphincter, there is another, made with the striated muscle - **m. sphincter urethrae externus**.

## Links

### Related articles

- Urinary tract
- Diuresis
- Male genital tract

### External links

- Urinary tract-Photographic interactive human atlas (<http://www.atlascloveka.upol.cz/cs/cs02/cs0206/cs020602.html>),
- Male urethra anatomy – Medscape (<https://emedicine.medscape.com/article/1972482-overview>)
- Female urethra anatomy – Medscape (<https://emedicine.medscape.com/article/1972504-overview>)

## References

ČIHÁK, Radomír – GRIM, Miloš. *Anatomie*. 2. 3. edition. Grada, 2013. ISBN 978-80-247-4788-0.