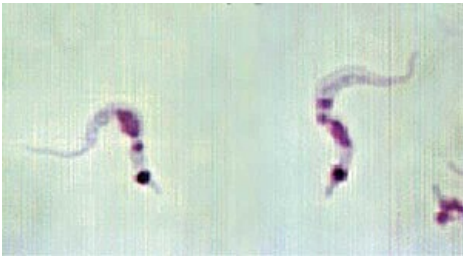


# Trypanosoma cruzi

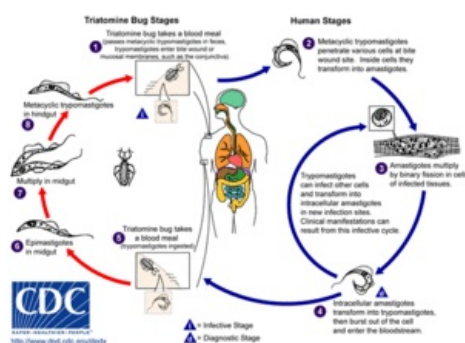
<i>Trypanosoma cruzi</i>	
Kinetoplasty (whips)	
Trypanosomatidae	
 <p>Trypanosomes cruzi trapped in the digestive tract</p>	
<b>Occurrence</b>	Central and South America
<b>Disease</b>	Chagas disease (American trypanosomiasis)
<b>Infectious stage and method of infection</b>	metacyclic trypomastigote - contaminating (from faeces of sucking bedbugs)
<b>Diagnostics</b>	microscopy, serology, xenodiagnosis (sucking of bugs)
<b>Therapy</b>	does not exist
<b>MeSH ID</b>	D014349 ( <a href="https://www.medvik.cz/bmc/link.do?id=D014349">https://www.medvik.cz/bmc/link.do?id=D014349</a> )

*Trypanosoma cruzi* is an element that causes **Chagas' disease** (also **American trypanosomiasis**). It belongs to the whipworms. It has a size of 15-20 µm, a wavy body shape and one flagellum, which forms an undulating membrane along the body. They do not form cysts or other resistant stages. It undergoes development in the **digestive tract of the bug** and transmits faeces, which the bug discharges to the skin during sucking (a contaminating mode of transmission). A person can also become infected by transfusion of infected blood (15%), from mother to fetus (1-2%) or by organ transplantation.

## Occurrence

- It is actually an American variant of African trypanosomes. It occurs in **Central and South America** and **Mexico**.
- It is an extremely rare imported disease in the Czech Republic.

## Life cycle



Life cycle of *T. cruzi*

Trypanosomes multiply in the **intestine of bugs** (subfamily *Triatominae*) in the form of *epimastigotes*, which turn into **infectious trypomastigotes** in the rectum of bugs. The infected bedbug attaches to humans (especially at night) and begins to suck. During sucking, the bugs harden on the skin, the trypanosomes present in the feces reach the skin, and so the so-called **contaminating mode of transmission** occurs.

Subsequently, trypanosomes actively penetrate the skin, where they multiply in a whipless form as an amastigote inside **non-phagocytic nuclear cells** (endothelial cells, muscle cells of all types, neuroglia). After several divisions, shortly before the cell ruptures, amastigotes turn into **trypomastigotes**, which are released into the bloodstream and initiate infection of other cells. The cycle ends when another bug sucks the blood of the infected person.

## Clinical picture

*Trypanosoma cruzi* causes **Chagas' disease**. Occurs only in America. It typically takes place in **3 phases**.



Roman syndrome in Chagas disease

### Acute phase

It appears **1 to 4 months** after the bite. **A small inflammatory infiltrate** develops at the site of the bite, but otherwise the course may be asymptomatic. In the case of conjunctival infestation, a characteristic one-sided conjunctivitis and swelling of the eyelids is created - the so-called **Román's syndrome**. Children have **irregular fevers**, hepatosplenomegaly, myocarditis, edema, bleeding disorders and neurological disorders.

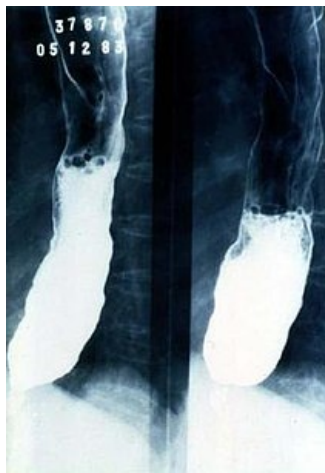### Latent phase

It appears **8 to 10 weeks** after infection, but can last for several years. It is characterized by the multiplication of parasites in tissues, which is often **asymptomatic**.

### Chronic phase

It lasts **10 to 30 years or even a lifetime**. *Trypanosoma* causes chronic changes in the heart such as cardiomegaly, left ventricular dilatation or **apical** aneurysm (50%) - aneurysm at the apex of the heart.

- **Symptoms of chronic heart disease** (30%), symptoms: shortness of breath, swelling of the legs, joints, chest pain, heart disorders, heart failure, sudden death.
- **Symptoms of chronic GIT disease** (6%): swallowing disorders, excessive salivation, food regurgitation, constipation, pain, **enteromegaly** (megaesophagus, megacolon).



Megaesophagus

## Prognosis and complications

⚠ The prognosis is bad. Mortality is **up to 50% during the 1st week**. In addition, serious complications are myocarditis and meningoencephalitis, which can be fatal. If the patient survives, he suffers **permanent neurological damage**.

## Diagnosis

We choose a suitable method according to the stage of the disease or according to the type of transmission.

- In **the acute phase**, trypanosomes in tears (Roman's symptom), peripheral blood, and white blood cell concentrate ( *buffy coat* ) can be directly detected. We will use microscopy (native or stained specimen), culture, xenodiagnosics (direct detection of trypanosomes in the blood using laboratory-reared bugs in the chamber).
- In the **latent and chronic phases**, we look for specific serum antibodies (IgG) in the blood or use xenodiagnosics.

If we suspect that trypanosomes have been **transferred from mother to child** (transplacental transmission), then we can:

- directly detect trypanosomes **in the newborn's blood** (concentration by microhematocrit centrifugation, culture, PCR is required),
- examine **specific serum antibodies** in both mother and child,
- histologically examine the **placenta and / or umbilical cord** and directly show amastigotes.

## Therapy

- There is **no therapy**, nifurtimox and benznidazole are partially effective.

## Links

### Related articles

- Trypanosomes
- Zoonoses
- Sleeping sickness

### Reference

1. BERMUDEZ, José, Carolina DAVIES a Analía SIMONAZZI. Current drug therapy and pharmaceutical challenges for Chagas disease. *Acta Tropica*. 2016, vol. 156, s. 1-16, ISSN 0001-706X. DOI: 10.1016/j.actatropica.2015.12.017.

### External links

- Lékaři bez hranic: Boj s opomíjenými tropickými nemocemi pokračuje (<https://www.lekari-bez-hranic.cz/article/novy-report-lekaru-bez-hranic-boj-s-opomijenymi-tropickymi-nemocemi-pokracuje>),

### Použitá literatura

- BEDNÁŘ, Marek, A SOUČEK a V FRAŇKOVÁ, et al. *LÉKAŘSKÁ MIKROBIOLOGIE : Bakteriologie, virologie, parazitologie*. 1. vydání. Triton, 1996. 560 s. ISBN 859-4-315-0528-0.

- NOHÝNKOVÁ, Eva. *Africké a americké trypanosomy - původci spavé a Chagasovy nemoci* [přednáška k předmětu Parazitologie, obor Všeobecné lékařství, 1. LF Univerzita Karlova]. Praha. 23. 11. 2015.
- 
- 

Template:Navbox - paraziti