

# Tromboembolic disease

Thromboembolic disease refers to a **group of thrombophilic conditions** and their consequences:

- arterial thrombi and embolisms,
- thrombophlebitis,
- deep vein thrombosis, post-phlebitic syndrome, pulmonary embolism,
- DIC,
- mesenteric vascular occlusion.

In a narrower concept, thromboembolic disease is mainly understood as deep vein thrombosis (deep vein DK) and its complications (pulmonary embolism, post-phlebitic syndrome).

## Pathophysiology

- **Virchow's trias - wall damage, slowing of blood flow, hypercoagulability,**
- thrombosis begins with platelet adhesion, fibrin deposition - **white thrombus,**
- a white thrombus can close the lumen, and stagnant blood forms a **red thrombus,**
- thrombosis stimulates inflammation in the wall leading to fibroblastic organization of the thrombus - after a few weeks, spontaneous recanalization may occur, but the valves remain damaged.

## Thrombophlebitis of superficial veins

**Thrombophlebitis of superficial veins** (thrombophlebitis superficialis) is a combination of thrombosis and inflammation of the vein wall. If the varices are also affected, it is varicophlebitis.

### Causes

It is often an idiopathic disorder. It can arise iatrogenically as a result of **long-term** cannulation , as a result of mechanical irritation or infusion of substances that irritate the endothelium. It often arises in a pathologically changed vein (varix) or in **systemic diseases** (Bürger's disease , collagenoses, malignancies). Thrombophlebitis can be one of the manifestations of TEN . Less often, it is an inflammation of bacterial etiology.

### Clinical Implications

**Redness and a painful infiltrate appear along the vein** , the area around the vein is **locally warmer** , often also general symptoms - temperature.

### Diagnostics

Thrombophlebitis can be diagnosed by clinical examination according to local inflammatory manifestations. The extent and event can be determined sonographically. simultaneous involvement of deep veins. If thrombophlebitis is near the saphenopopliteal or saphenofemoral junction, duplex ultrasonography should be performed to rule out DVT.

### Therapy

It consists of:

- elimination of the cause, if known (e.g. infusion),
- cold compresses and ointments with heparin,
- general or local administration of NSAIDs ,
- compression compress,
- ATBs are not routinely used in uncomplicated thrombophlebitis.

### Complications

- relapses
- if the thrombus is in the junction area, complications such as DVT are common
- there is also a risk of PE in untreated thrombophlebitis of the proximal trunk of the saphenous vein

**⚠ Attention! CAVE! If the localization of thrombophlebitis is within 5 cm of the saphenofemoral or saphenopopliteal junction, there is a high risk of DVT or PE and anticoagulant treatment is necessary .**

## Deep vein thrombosis

**This article was marked by its author as *Under construction*, but the last edit is older than 30 days.** If you want to edit this page, please try to contact its author first (you will find him in the history ([https://www.wikilectures.eu/index.php?title=Tromboembolic\\_disease&action=history](https://www.wikilectures.eu/index.php?title=Tromboembolic_disease&action=history))). Watch the page as well. If the author will not continue in work, remove the template {{Under construction}} and the page.

Last update: Friday, 23 Dec 2022 at 9.21 pm.

Deep vein thrombosis is the most often cause of pulmonary embolism. Thrombosis is localized in deep vein system of lower limb (but the same type of thrombosis can be localized in deep vein system of upper limb). Typical localization is deep vein of lower leg, popliteal vein, femoral vein, iliac vein.

## Pathophysiology

Virchow's triad:

- endothelial dysfunction,
- blood flow deceleration,
- blood hyperviscosity (change in the composition of blood).

There is an equilibrium in blood clotting in common situation. For thrombus formation is necessary impulse.

## High Risk Patient

We have several groups of patients with high risk of thrombus formation:

- **patients with inborn risk:**
  - protein C or protein S deficiency
  - Leiden's mutation
  - elevated level of clotting factors (II, ...)
- **patients with acquired risk:**
  - immobilization
  - surgery (abdominal surgery, oncosurgery, orthopedics - total endoprosthesis)
  - trauma
  - hormonal contraception
  - infection
  - central vein catheter (typically in subclavian artery)
  - pregnancy - especially the 2<sup>nd</sup> and 3<sup>rd</sup> trimester (because of physiological elevation of clotting factors)
  - postpartum period

## Diagnostic

### Symptoms

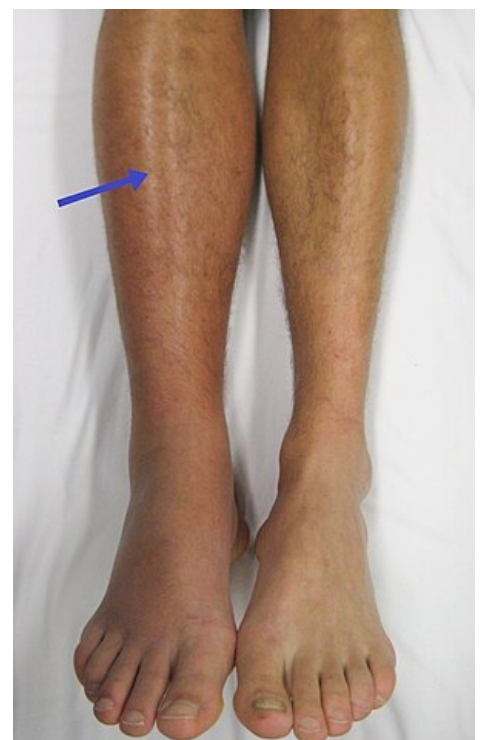- pain - painful palpation, painful dorsiflexion of foot (Homans sign)
- edema - because of decreased vein blood drainage, greater limb circumference
- peripheral (superficial) vein dilatation - because of decreased vein blood drainage, superficial veins must take greater amount of blood
- peripheral pulsation can not disappear just only because of deep vein thrombosis, there must be affected arteries

### Diagnostic Methods

- laboratory:
  - elevated D-dimers - thrombolysis marker
- duplex sonography - basic noninvasive method
- venography - with contrast agent
- CT angiography - in suspected iliac vein thrombosis

## Therapy

- **anticoagulation:**
  - **LMWH** - works immediately, preferred in pregnancy and short time therapy (acquired risk - surgery ...), e.g. fraxiparine, enoxaparine.
  - **heparin** - is less performed, just in patients with contraindicated LMWH or in patient suspected on pulmonary embolism
  - **warfarin** - peroral anticoagulant, unfortunately it takes several



Lower limb edema.

days (3-6) before in really starts work, but the patient should have specific therapy immediately (start with warfarin and LMWH in the same time and stop with LMWH in 4-5 days). This drug should be performed in patients with inborn high risk of thrombosis. Needed INR level is 2-3.

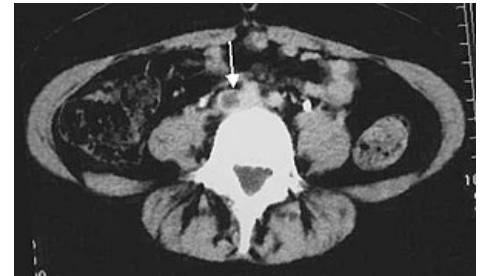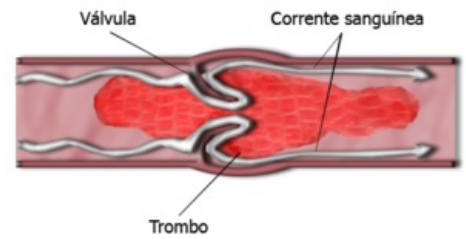
- **thrombolysis** - is an extensive method in patients with high iliac vein thrombosis, these patients are in high risk of pulmonary embolisation.

## Prevention

- soon mobilization of patients (after surgery)
- bandage of limbs
- LMWH before surgery

## Complications

- pulmonary embolization
- deep vein valves dysfunction
- deep vein system hypertension → vein insufficiency



CT, thrombus of iliac right vein.

## Links

### Related articles

- Pulmonary embolism
- Heparin
- Leiden mutation
- Thromboembolic disease in gynaecology
- Thromboembolic disease (paediatrics)
- Migratory thrombophlebitis

### External links

- Deep vein thrombosis, low molecular weight heparins, warfarinization, MUDr. A. Hluší, Department of Hemato-oncology, FN Olomouc (<http://public.fnol.cz/www/urgent/seminare/20061207/HZT.pdf>)

### Literature used

- WikiLectures.eu. *Deep Vein Thrombosis* [online]. [cit. 2012-02-11]. <[https://www.wikilectures.eu/index.php/Deep\\_Vein\\_Thrombosis](https://www.wikilectures.eu/index.php/Deep_Vein_Thrombosis)>.
- ČEŠKA, Richard, et al. *Internal*. 1. edition. Prague : Triton, 2010. 855 pp. pp. 209-212. ISBN 978-80-7387-423-0.
- BENEŠ, Jiří. *Study Materials* [online]. [cit. 29.6.2010]. <<http://jirben.wz.cz>>.