

Treatment of precancerous lesions of gynecological tumors

Precancerous lesions of gynecological tumors^{[1][2]} can be treated either surgically with a curative result, which is the most common procedure, or conservatively.

Surgical treatment

Surgical treatment may be **destructive** or **ablative**. During the destructive process, precancerous tissue is destroyed, so it can no longer be examined histologically. Therefore, it is necessary to take a biopsy sample prior to the procedure. Destructive methods are rarely used anymore. In the case of ablation, surgical removal of the tissue is performed, which can then be examined histologically.

Vulva

Excision of the lesion or skinning is performed.

Vagina

Among the destructive procedures is *laser vaporization*, which is no longer widely used. Of the ablative procedures, **laser ablation** is used, with a more radical approach: **partial** or even **total colpectomy**.

Cervix

Coblation or **cylindrical dissection** is performed (ablative method).^[1] The **LEEP** (*loop electrosurgery excision procedure*) method is common, in which the cone of the cervix is cut out with an electrocoagulation loop. *Another option is the cold knife method. Laser ablation is rarely performed.*

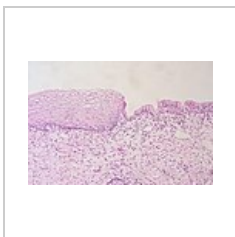
Endometrium

Hysterectomy with bilateral adnexectomy is performed. Fertility-preserving treatment is non-surgical (see below).


Non-surgical treatment

Immunomodulatory treatment against HPV with **Imiquimod** can be used for precancerous lesions of the vulva and vagina. In endometrial precancerous disease, progestogen therapy can be used to preserve the uterus and achieve the regression of the lesion.

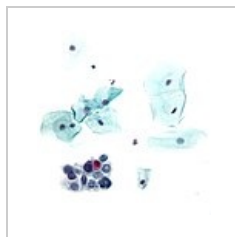Gallery



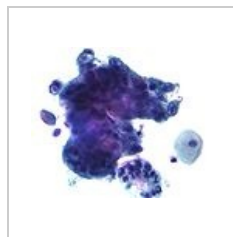
Physiological appearance of the cervicovaginal junction



LSIL: cells with enlarged nucleus and irregular chromatin



HSIL: smaller tumor cells with enlarged nucleus and irregular chromatin



Adenocarcinoma: tumor cells filled with intracytoplasmic vacuoles with mucus

References

Related articles

- Precancerous lesions in gynecology
- Cervical precancerous lesions

Citations

1. SLÁMA, Jiří. *Prekancerózy rodidel* [přednáška k předmětu Gynekologie a porodnictví předstátnicová stáž, obor Všeobecné lékařství, 1. lékařská fakulta Univerzita Karlova v Praze]. Praha. 13.2.2014.
2. ROB, Lukáš, Alois MARTAN a Karel CITTEBART. *Gynekologie*. 2. vydání. Praha : Galén, 2008. 390 s. s. 179-213. ISBN 978-80-7262-501-7.

