

Supraspinatus tendon tear

Rupture of the m.supraspinatus tendon occurs most often during its degenerative changes, which are preceded by signs of impingement syndrome.

Clinical manifestation

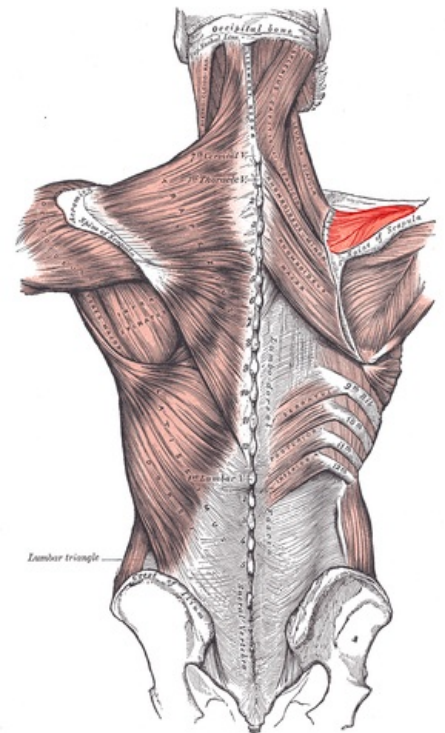
- **incapability** of an active **elevation** of the upper arm between **60°-120°**;
- passive elevation is possible;
- positive drop test;
- positive Gerber test.

Diagnostics

- in addition to symptoms, ultrasound and nuclear magnetic resonance can be performed.

Treatment

- **Conservative**
 - in *elderly* patients;
 - orthosis, abduction splint.
- **Surgical**
 - in younger and physically active patients;
 - *suture* or *reinsertion*.



Posterior view of muscles connecting the upper extremity to the vertebral column

Links

Related articles

- Muscles of the upper limb
- Humeral head fractures

Source

- PASTOR, Jan. *Langenbeck's medical web page* [online]. [cit. 2009]. <<https://langenbeck.webs.com/>>.