

# Subclavian Artery

## Progress

**A. subclavia'** arises on the right from the *truncus brachiocephalicus* and on the left from the *arcus aortae*. Subsequently, it progresses upwards in the chest and then turns laterally through the cupula pleurae and the 1st rib through the fissura scalenorum into the axilla.

It supplies the brain, the cervical part of the spinal cord, the cervical spine and the muscles around it, the entire first two intercostals and the front sections 3-11. intercostals, anterior mediastinum, pericardium, diaphragm, thyroid gland, larynx, part of the muscles and skin of the neck, chest and spine and the upper half of the rectus abdominis muscle.

## Branching

### Pars intrascalenica

#### A. vertebralis

It enters the foramen of the processus transversi of the C6 vertebra and continues through these openings cranially to the atlas.

Between the axis and the atlas, it makes a vertical arch, convex laterally, and between the atlas and the occipital axis a horizontal arch, convex dorsally, through which it inserts into the sulcus arteriae vertebralis of the atlas and along the inner side of the massa lateralis passes through the membrana atlantooccipitalis posterior and through the dura into the foramen magnum and onto the clivus, where the right and left a. vertebralis join into the unpaired **a. basilaris'**, which subsequently divides into the right and left **a. cerebri posterior**, into which enter the right and left a. communicans posterior (from a. carotis interna) - part of the *circulus arteriosus cerebri* (Willis).

It supplies the deep muscles located at the cervical spine, the spinal ganglia, the sheaths of the spinal cord and spinal cord, the dura mater in the part of the posterior cranial fossa and the brain.

### Branching

- on the neck - *rr. spinales, rr. musculares, r. meningeus*;
- in the skull - *a. basilaris, a. cerebri posterior (dextra, sinistra)*, branches for the spinal cord and brain.

#### A. thoracica interna

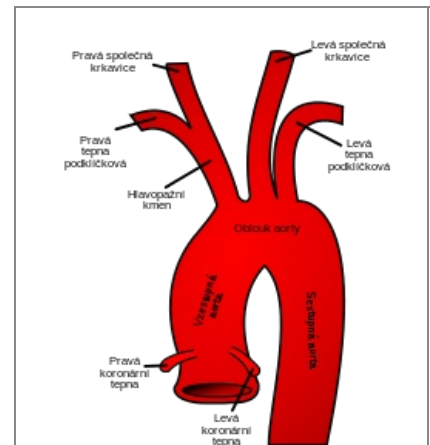
- rises against the a. vertebralis and descends through the anterior mediastinum behind the costal cartilages about 1 cm from the sternum;
- passing through the trigonum sternocostale, the diaphragm continues as a. epigastrica superior into the sheath of the m. rectus abdominis and anastomoses with the branches of a. epigastrica inferior.

It supplies the front sections of all intercostal spaces and the sternum, thymus, bronchi, pericardium, part of the diaphragm and the rectus abdominis muscle, the adjacent skin area and, in women, the mammary gland.

### Branching

- *a. pericardiophrenica* - together with n. phrenicus progresses along the side wall of the pericardium to the diaphragm;
- *rr. mediastinales* - *rr. thymicae, rr. sternales, rr. bronchiales*;
- *rr. intercostales anteriores* - *rr. perforantes* - through the muscles to the skin and later branches to the muscles, skin and, in women, to the mammary gland;
- *a. musculophrenica* - terminal branch - issues *rr. intercostales anteriores* for 5 lower intercostal spaces;
- *a. epigastrica superior* - final branch- descends along the back of the m. rectus abdominis in its sheath and supplies its cranial parts.

### Truncus thyrocervicalis



A12.2.08.001 (<http://www.unifr.ch/ifaa/Public/EntryPage/TA98%20Tree/Entity%20TA98%20EN/12.2.08.001%20Entity%20TA98%20EN.htm>)

#### pars intrascalenica:

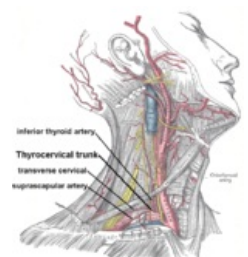a. vertebralis, a. thoracica int., truncus thyrocervicalis (a. thyroidea inf., a. cervicalis ascendens, a. cervicalis spf., a. suprascapularis); **pars**

#### interscalenica:

truncus costocervicalis (a. cervicalis prof., a. intercostalis suprema);

#### pars extrascalenica:

a. transversa colli  
a. axillaris



A. subclavian and some of its branches

It supplies the thyroid gland and larynx, part of the mediastinum, the deep muscles of the neck, the muscles and skin of the regio colli lateralis and the muscles of the dorsal side of the scapula.

It emerges cranially at the front edge of the scalenus anterior muscle and is divided into:

- *a. thyroidea inferior* – first it rises to the C6 vertebra, then it turns sharply mediocaudally, crosses the neurovascular bundle of the neck and goes to the lower pole of the thyroid gland and divides into:
  1. *a. laryngea inferior* – for the larynx, anastomoses with *a. laryngea superior* from *a. thyroidea superior*;
  2. *rr. glandulares*;
  3. branches for pharynx, esophagus, trachea and thymus.
- *a. cervicalis ascendens*' - along the n. phrenicus progresses cranially along the scalenus anterior muscle, it is often a branch of the *a. thyroidea inferior*;
- *a. cervicalis superficialis* - trigonum colli laterale further branches to the muscles and skin, it is often a branch of *a. transversa colli* and then it is called *r. superficialis arteriae transversae colli*;
- *a. suprascapularis* - anastomoses with *a. circumflexa scapulae*.

## Pars interscalenica

### Truncus costocervicalis

It recedes behind the scalenus anterior dorsally and divides into the ascending ``*a. cervicalis profunda* and the descending ``*a. intercostalis suprema*.

It supplies the posterior part of the 1st and 2nd intercostals, the deep neck muscles and participates in the supply of the spinal canal and the spinal cord.

## Pars extrascalenica

### A. transversa colli

- sometimes arises from the truncus thyrocervicalis.

It supplies the neck muscles, girdle muscles of the upper limb and the trapezius muscle.

### Branches

- *r. superficialis*
- *r. profundus*

## Links

## Related Articles

- Aorta

## References

- ŠIHÁK, Radomír – GRIM, Miloš. *Anatomy*. 2nd, edited and supplemented edition. Grada Publishing, 2004. 673 pp. vol. 3. ISBN 80-247-1132-X.