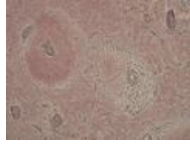


Silver impregnation



This method is used, for example, to show reticular ligament, which occurs in secondary lymphatic organs (lymph nodes, spleens, tonsils) and bone marrow. Metallic silver is reduced from silver nitrate (AgNO_3), which gives the reticular fibers a dark brown to black color.

Slezina8.jpg



Links

Related articles

- AZAN
- Hematoxylin-eosin staining
- Resorcin-fuchsin