


Shock

Shock is a sudden life-threatening condition of impaired tissue perfusion that can lead to organ changes.

Tissue perfusion has both a **nutritional component** and a **circulatory component**.

Shock definition:



- Nutritional component: Delivery of oxygen and nutrients to cells and removal of carbon dioxide and metabolites.
- Circulation component: Maintaining perfusion is necessary for **the distribution of cardiac output** among individual organs and for maintaining arterial blood pressure.

On the one hand, it is necessary to ensure **tissue nutrition** (vasodilatation), on the other hand, to **maintain arterial pressure** (vasoconstriction). In the case of shock, these two functions come into conflict. Eventually, the need for tissue nutrition prevails and **vasodilation and hypotension occur**. The shock from any cause usually turns into a form of vasodilatory shock, which, together with other factors, can cause damage to a vital organ. It usually affects several organs at the same time and thus MODS (*multi-organ dysfunction syndrome*) develops. Hypoperfusion can be caused by:

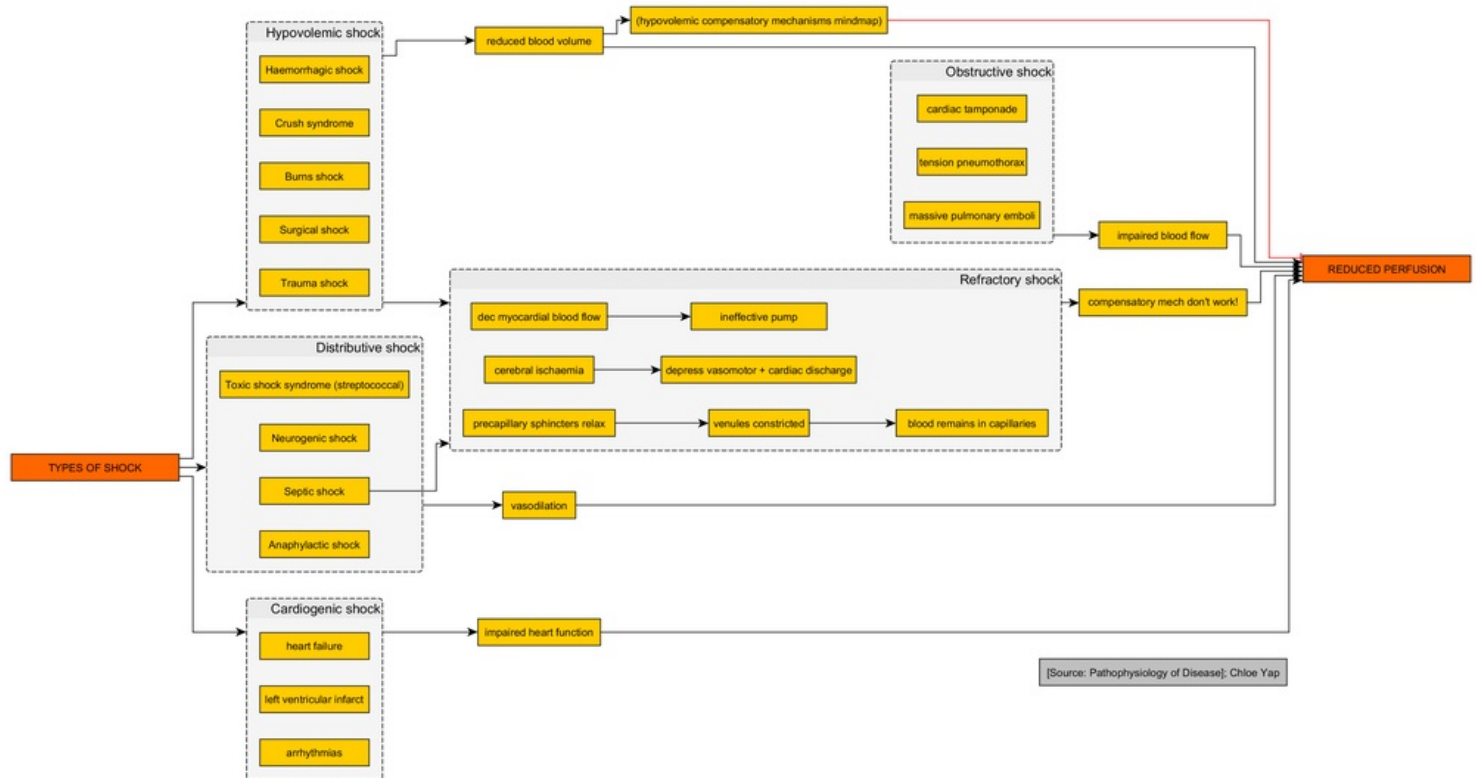
- **decrease in pressure gradient** (hypotension) – decrease in cardiac output
- **reduction of the peripheral resistance of the vascular bed** – vasodilation

Causes of shock

- conditions causing a **decrease in cardiac output** – hypovolemia, heart failure,
- **generalized vasodilatation** – anaphylaxis, sepsis, neurogenic cause.

Characteristic symptoms of shock

- Sudden arterial hypotension, systolic pressure **below 90 mmHg**.
- Pressure reduction-induced activation of **the sympathoadrenal system**.
- Capillary return longer than 2 s.
- Cold, clammy, cyanotic skin.
- **Lactic acidosis** from the transition to anaerobic metabolism.
- Reduction of **cardiac index** (MCO/body surface area) **below 1.8**.



Types of shock

Pathogenesis of shock

The shock has three successive phases – the compensation phase, the decompensation phase and the irreversible phase.

The compensation phase

The body's compensatory reaction is an effort to maintain sufficient perfusion of vitally important tissues at the expense of hypoperfusion of other tissues. There is a **centralization of circulation**. The basis of compensation is an activation of the sympathoadrenal system conditioned by hypotension. There is a **washout of catecholamines** (adrenaline, noradrenaline), which leads to a redistribution of the blood:

- **vitally important tissues** – brain, myocardium, adrenal glands, diaphragm, hepatic artery,
 - vasodilatation (adrenaline effect on β -receptors) and thus increased perfusion and blood supply to these organs,
- **less important tissues** – skin, skeletal muscles, lungs, intestine, pancreas, kidneys, spleen,
 - vasoconstriction (effect of noradrenaline and adrenaline on α -receptors), thereby reducing perfusion and causing ischemic hypoxia of these tissues.

The blood volume moves to the vital tissues for the most part, the arterial pressure is normal or stably reduced in this phase. Another effect of catecholamines is **an acceleration of the breathing, an increase in heart rate and strength of myocardial contraction**. Other phenomena are:

- *autoinfusion* – due to a drop in pressure in the initial stages of shock, fluid will be sucked from the interstitium into the vessels,
- *autotransfusion* – contraction of blood vessels in the capacity part of the bloodstream (especially the liver, spleen and chest area) leads to the transfer of blood reserves from these organs to active circulation.

The decompensation phase

Vasodilation occurs in **hypoperfused tissues**. Hypoperfusion in "less important tissues" leads to their hypoxic damage, **O₂ tension and pH decrease, CO₂ tension increases**. This leads to the relaxation of vascular smooth muscle and vasodilation in the precapillary region, postcapillary resistance vessels remain contracted. It leads to:

- change of **ischemic hypoxia** into **stagnant**,
- extravascular **fluid penetration** → **deepening of hypovolemia**,
- reduction of fluid volume in the "centralized circulation" → **deepening of hypotension**,
- the release of **metabolites** and **enzymes** from damaged cells (e.g. during ischemia of the GIT and pancreas, the so-called *myocardial depressor factor* is released, which has a negative inotropic effect on the myocardium),
- **hypoxic-reperfusion damage** to ischemic tissues (increased expression of the enzyme xanthine oxidase leads to increased production of oxygen radicals),
- release of **tissue factor** from damaged tissues – formation of *DIC* (also supported by hemoconcentration in capillaries from which fluid leaks into the interstitium).

The irreversible phase

The changes are uncompensated and irreparable, there is permanent damage to organs and even death.

Organ changes in shock

During shock, individual organs fail only exceptionally, often entire systems fail and the condition progresses to MODS. Morphological findings in shock (primarily microscopic) are **circulatory disorders** (capillarovenous congestion – hyperemia, swelling, platelet thrombi in capillaries) and **consequences of hypoxia** (dystrophic changes up to necrosis). A distinction must be made between **milder dysfunction** (functional disability) called **organ in shock** and between **more severe functional and structural disability** (so-called shock organ). **The most affected** are those organs in which **vasoconstriction and thus hypoperfusion occurs** in the early stages of shock.

Lungs

Activation of the sympathoadrenal axis leads to **tachypnea**, however, with reduced MCO, **pulmonary perfusion decreases**. The ventilation-perfusion ratio is disturbed, only the lower parts of the lungs are supplied with blood, and the upper lobes represent dead space. **Gas exchange is disrupted, hypoxia** occurs, which leads to damage to the endothelium of the pulmonary capillaries and the release of proteolytic enzymes from neutrophils. There is **interstitial pulmonary edema**, which is visible on X-ray as a milky pulmonary pattern. Disruption of surfactant production leads to **microatelectases** (collapse of alveoli, exfoliated membranous pneumocytes together with fibrin form the so-called **hyaline blanks filling the alveoli**).

- Macroscopically, **the lung is heavy and moist**;
- Microscopically, we observe the strengthening of septa and effusion in the alveoli.

This condition is manifested by **acute pulmonary insufficiency**, initially characterized by hypoxemia and hypocapnia. The phase of functional changes is referred to as **ALI** (acute lung injury). Organic damage leads to a condition called **shock lung - DAD** (*diffuse alveolar damage*) is clinically manifested as **ARDS** (*acute respiratory distress syndrome*).

Kidney

Hypotension and vasoconstriction in the kidneys leads to their **reduced perfusion** and to a **decrease or stoppage of glomerular filtration**. This is manifested by **oliguria** to **anuria**. In the initial stages of shock, it serves to maintain the intravascular volume. However, after ischemia lasting more than 90 minutes, the functional disorder turns into a morphological one and **renal failure** occurs.

Shock kidney

- Macroscopically **pale, enlarged**;
- Microscopically, **necrosis of the lining of the proximal tubules, interstitial edema**, penetration of erythrocytes into the tubules, where they form pigmented hemoglobin cylinders.

Intestine

Hypoperfusion of the intestine leads, after a certain period of time, to **damage with disruption of the intestinal barrier with swelling and bleeding**, especially in the upper parts of the small intestine, which are followed by the penetration of bacteria, the penetration of toxins, the release of endotoxin, histamine, cytokines (IL-1, IL-6, TNF- α) and other mediators of inflammation (e.g. myocardial depressor factor from a damaged pancreas), which often result in SIRS and sepsis and **deepen shock**.

Liver

The liver plays, among other things, an important immunological role (*Kupffer cells*), because blood flows through them from the intestines before it reaches the lungs. When this function of the liver is damaged, the **penetration of bacteria and their toxins into the lungs is facilitated**, which further promotes the development of ARDS. During the shock, hepatocytes also decrease, thereby reducing the breakdown of toxic metabolic products, and the synthesis of acute phase proteins. Jaundice may also occur, which is a very unfavorable prognostic sign.

- microscopically **centrolobular necrosis**

Heart

The heart is affected by insufficient oxygen supply to the myocardium, which cannot be regulated even by normal mechanisms (coronal vasodilation). Lack of blood is manifested by the occurrence of arrhythmias.

Brain

Anoxic encephalopathy develops up to small infarcts in the border zones between the basins of cerebral arteries, which leads to the formation of small necroses.

Lymphatic tissues

Selective necrosis of the germinal centers (especially the spleen, and thymus) due to glucocorticoids released from the adrenal cortex.

Adrenal glands

Depletion of lipids under the influence of ACTH released from hypophysis during shock leads to a mutual

distance and narrowing of the beams of the cortex, which then resemble tubules - so-called **pseudotubular degeneration** in the outer part of the zona fasciculata, sometimes **even hemorrhagic necrosis of the adrenal cortex (Waterhouse-Friderichsen syndrome)** in meningococcal sepsis).

Shock division

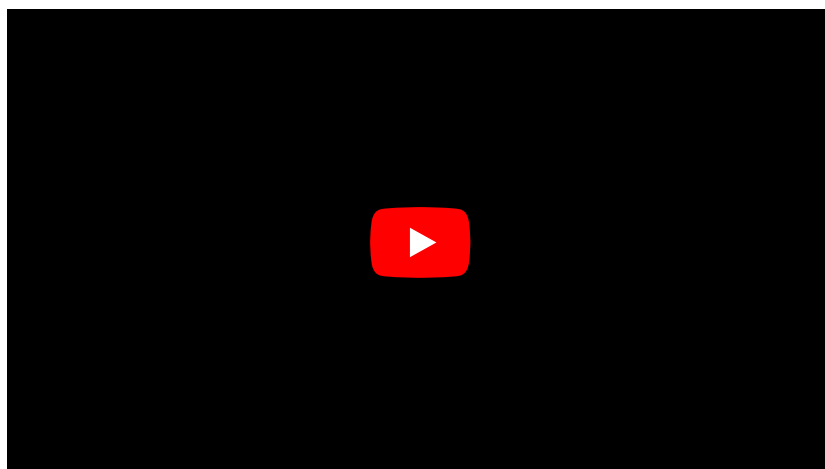

By the pathogenesis

- hypovolemic.
- cardiogenic.
- obstructive.
- distributive (peripheral, vasodilatory).
 - septic,
 - anaphylactic,
 - neurogenic,
 - endocrine.

By the cause

- hypovolemic,
 - hemorrhagic, (traumatic and non-traumatic bleeding)
 - burn,
 - dehydrating,
- cardiogenic,
- anaphylactic,
- septic,
- neurogenic.

Summary videos





Links

Related Articles

- Shock (pediatrics)
- Circulatory shock
- Shock - polytrauma
- Shock (obstetrics)

References

- PASTOR, Jan. *Langenbeck's medical web page* [online]. [cit. 29.5.2010]. <<https://langenbeck.webs.com/>>.
- ZEMAN, Miroslav, et al. *Chirurgická propedeutika*. 3. edition. Grada, 2011. 512 pp. pp. 374-376. ISBN 978-80-247-3770-6.



This article is a stub.

You can join the authors (<https://www.wikilectures.eu/index.php?title=Shock&action=history>) and it. You can discuss the changes at discussion.
