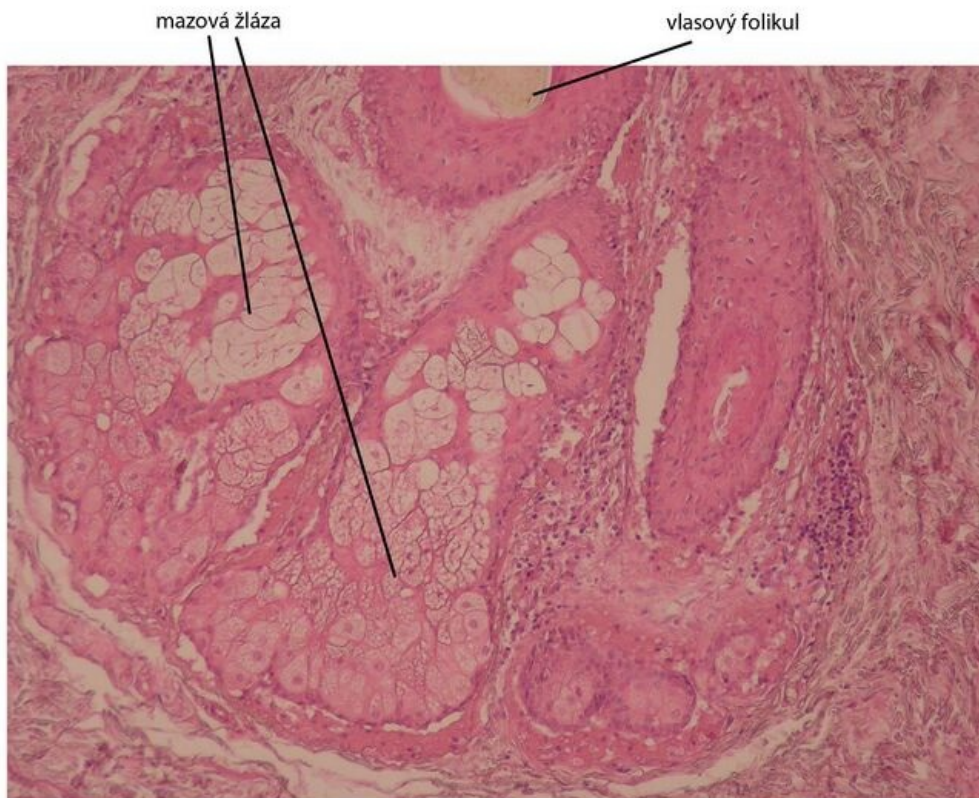


Sebaceous gland (picture)



Holokrinní sekrece - mazová žláza - preparát axilla, barveno H&E

Holocrine mode of secretion