

# Pathology of lymphatic vessels

**Lymphatic vessels** are thin vessels lined by the endothelium in which the lymph flows. They are *difficult to see macroscopically* because they *are collapsed*. The lymphatic system begins blindly in the tissues and joins into major lymphatic strains. These strains have a thin layer of smooth muscle and **valves**. Its function is to drain part of the interstitial fluid (*tissue fluid*). In a pathological condition, infections or tumors can be spread by lymphogenic vessels. Lymphatic vessel diseases include: **lymphangiitis**, **lymphoangiopathy carcinomatosa**, **lymphedema**, **lymphorrhage** and **lymphangiomas**.

## Lymphangiitis

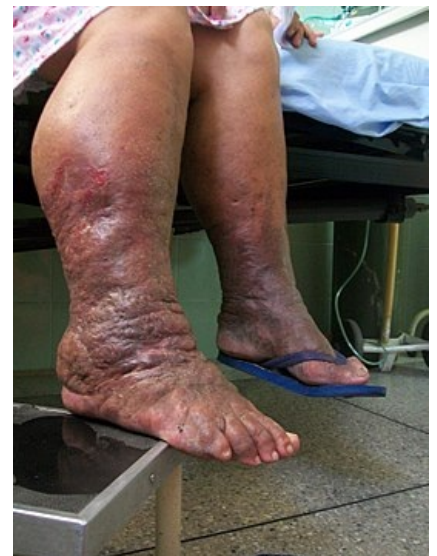- It is an **acute inflammation** of the lymphatic vessels.
- *Pyogenic bacteria* ( $\beta$ -hemolytic streptococcus) are the most common cause.
- The infection can often spread to regional lymph nodes, from which it can travel to the blood and cause *bacteremia* or even *sepsis*.
- **Clinical signs:** a red, hard and painful stripe under the skin that copies the way of a blood vessel.

## Lymphangiopathia carcinomatosa

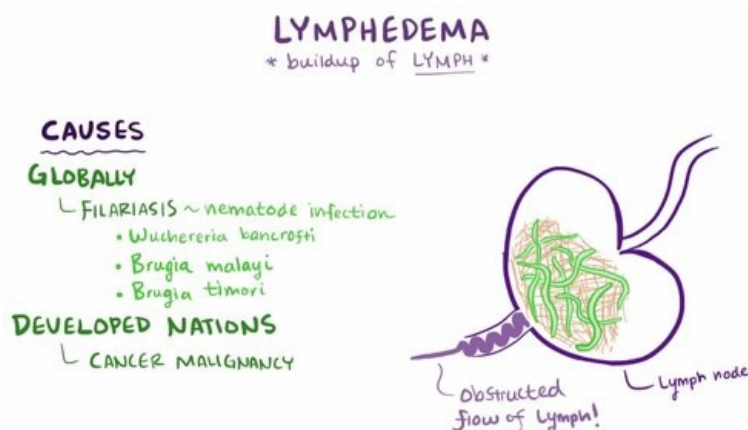
- It is a significant dilation of small lymphatic vessels by malignant tumor cells.
- It occurs most often in **the lungs**.
- Lymphatic vessels are macroscopically visible as *white branching streaks* in the pleura. These streaks are also around the bronchi and branches of the pulmonary artery.
- **Clinical signs:** severe dyspnoea.

## Lymphedema

- It is the swelling caused by a **disorder of lymph drainage**.
- It arises from *chronic obstruction* of lymphatic vessels, which is accompanied by venostasis (mainly on the limbs).
- It can occur secondarily *after infection*, when the lymphatic vessels become scarred.
- It occurs very often in **women with breast cancer**. Lymphedema occurs as a result of surgical treatment or tumor infiltration of the lymph node or after irradiation.
- In the *tropics*, it is caused by *filarioides*.
- Rarely, it can be caused by congenital malformations of the lymphatic vessels.
- **Clinical signs:** the limb is heavily swollen, initially pasty in consistency. Later, it is stiffer (due to fiber production) and the skin has an appearance of orange peel. Trophic and inflammatory changes occur on the skin secondarily.
- Lymphedema itself is not life-threatening.



Lymphedema



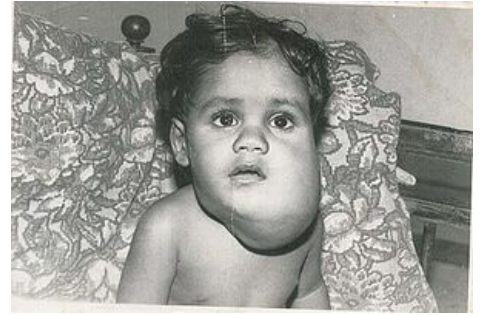## Lymphorrhage

- Also *lymphorea*.
- There is a **leakage** of milky lymph from the lymphatic vessels.

- It is caused by mechanical damage, tumor obstruction or spontaneous rupture of the *ductus thoracicus*.
- Lymph can accumulate in the chest and cause *chylothorax*, or in the abdominal cavity and cause *ascites chylosus*.

## Lymphangioma

- Lymphatic vessel **tumors**.
- They are analogous to hemangiomas but do not contain erythrocytes.
- They are less common and almost always **benign**.
- They occur mainly in the skin and subcutaneous tissue, in the organs of the abdominal cavity and in the retroperitoneum.
- We distinguish: capillary, cavernous and cystic lymphangiomas.
- - **Capillary lymphangioma** occurs in the skin and mucosa of the upper small intestine. *Chylangioma* - capillary lymphangioma in the mucosa of the upper small intestine.
  - **Cystic lymphangioma** is the only *clinically significant* one. It arises as a congenital swelling in the subcutaneous tissue of the neck - **hygroma colli cysticum**. Sometimes it reaches large dimensions - except for the face and the axilla. It *grows infiltratively* into soft tissues, so it is difficult to resect and often recurs after surgery.



Lymphangioma

 For more information see *Lymphangioma*.

## Links

### Related articles

- Lymphatic system
- Vasculitis
- Development of lymphatic vessels, nodes and spleen

### Sources

- POVÝŠIL, Ctibor – ŠTEINER, Ivo – DUŠEK, Pavel, et al. *Special pathology*. 2. edition. Praha : Galén, 2007. 430 pp. ISBN 978-807262-494-2.