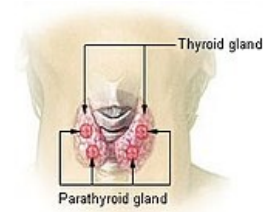


Parathyroid glands

The *parathyroid glands* (lat. glandulae parathyreoideae) are four small, lens-like formations on the back of the thyroid glands, enclosed in its capsule. They develop from the entoderm of the 3rd and 4th gill slits. Each corpuscle is enveloped by a capsule of collagenous tissue, from which thin septa depart, which increase in size with increasing age by the accumulation of adipocytes. The parenchyma is arranged in a trabecular epithelium, in which we find chief cells *and oxyphilic cells*.



Thyroid gland and parathyroid glands

Microscopic Structure

Chief cells

They represent the predominant element in the gland. These are polyhedral cells with spherical nuclei and light-staining cytoplasm with a diameter of 10 μm . They contain secretory granules exhibiting argyrophilic properties (they are impregnable with salts of heavy metals – Ag, Au). These cells produce parathormone, **which increases the level of calcium ions in the blood by increasing bone resorption and reabsorption in the kidney, and secondarily by stimulating hydroxylation of 25-hydrocholecalciferol in the kidney at position 1. This creates 1,25-dihydrocholecalciferol (calcitriol) increasing the absorption of calcium in the intestine.**

Oxyphilic cells

Polyhedral cells larger in size than the chief cells, their nuclei are relatively brightly colored. In the cytoplasm we find a large number of mitochondria (they condition its strong eosinophilia), glycogen granules, but no secretory granules. The cells appear postnatally, around the age of 10.

Links

Related Links

- Parathormone
- Thyroid
- Thyroid hormones and their functions in regulatory events
- Parathyroid disease

References

- KONRÁDOVÁ, Václava – UHLÍK, Jiří – VAJNER, Luděk. *Funkční histologie*. 1. edition. Jinočany : H & H, 2000. ISBN 80-86022-80-3.
- MESCHER, Anthony L – JUNQUEIRA, Luiz Carlos Uchôa. *Junqueira's Basic Histology*. 12. edition. United States : McGraw-Hill Education - Europe, 2009. 480 pp. ISBN 9780071630207.