

# Pancreatic neuroendocrine tumors

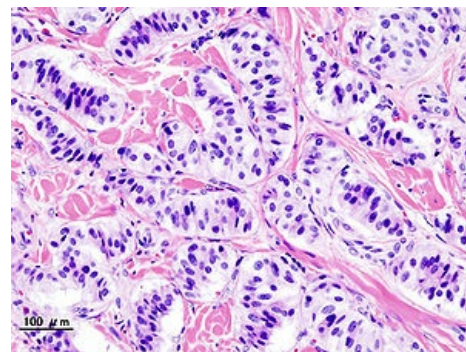
**Neuroendocrine tumors of the pancreas** include the **insulinoma**, **gastrinoma**, **glucagonoma**, **somatostatinoma**, **VIPoma**. Collectively, tumors arising from the cells of the islets of Langerhans are referred to as '**nesidiomas**'.

## Insulinoma

An insulinoma is in most cases a **benign** tumor (adenoma) originating from the **β-cells** of the islets of Langerhans producing insulin. The most common location is the head and body of the pancreas. The malignant variant (non-sidioblastoma) occurs only in about 5-10% of cases. Women are more often affected, it occurs between the ages of 20 and 75. a year. It is the most common of all pancreatic neuroendocrine tumors.

### Clinical picture

The classic manifestation is morning hypoglycemia as a result of excess insulin production, which mainly manifests itself in the fasting state. The most manifested neuroglycopenic symptoms are headaches, diplopia and impaired vision, behavioral changes, decreased concentration, speech and consciousness disorders. Manifestations of activation of the sympathoadrenal axis (sweating, palpitations, tachycardia) occur less often.



Pancreatic insulinoma

### Diagnostics

The most important criterion is the patient's clinical condition (see above). In insulinomas, a typical "**Whipple's triad**" is described:

1. laboratory-confirmed hypoglycemia ( $\leq 2.5$  mmol),
2. the presence of symptoms of hypoglycemia,
3. adjustment of state after administration of sweet food (glucose).

## Gastrinoma

 For more information see *Gastrinoma*.

## Glucagonoma

Tumor arising from the **A-cells** of the pancreas. It is relatively rare, but often **malignant** and metastatic. Clinical picture:

- necrolytic erythema migrans,
- increased catabolism,
- increased sugar level,
- dyslipidemia,
- cholelithiasis, steatorrhea.

## Somatostatin

Very rare, '*malignant*' with early metastases to the liver. Clinical picture:

- dyspepsia,
- diarrhea,
- weight loss,
- abdominal pain, cholelithiasis, steatorrhea,
- anemia.

## VIPoma

A rare tumor producing vasoactive intestinal peptide. Clinical picture:

- watery diarrhea, hypokalemia, acidosis.



You can join the authors ([https://www.wikilectures.eu/index.php?title=Pancreatic\\_neuroendocrine\\_tumors&action=history](https://www.wikilectures.eu/index.php?title=Pancreatic_neuroendocrine_tumors&action=history)) and it. You can discuss the changes at discussion.

---