

# Painful syndrome of the left lower abdomen

This article has been translated from WikiSkripta; ready for the **editor's review**.

Painful syndrome of the left lower abdomen has a lot of causes.

## 1. Leftsided renal colic

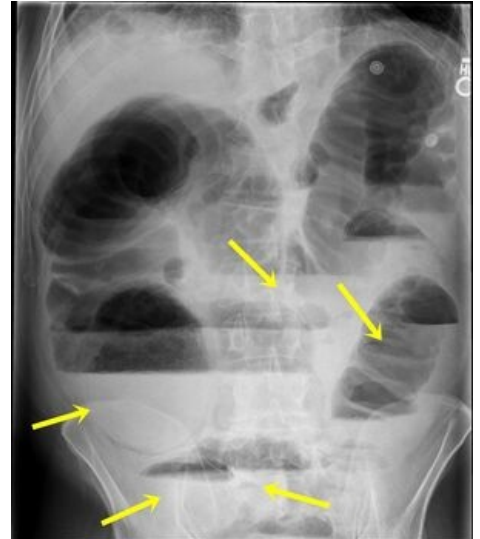
*You can find more information at article renal colic*

## 2. Ileus

- Often caused by rectosigmoid carcinoma, which is found in older patients with a long-term history of digestive problems (constipation, alternating constipation with diarrhea, enterorrhoea).
- Clinical picture: sudden pain in the left lower abdomen with bloating, stoppage of passing gas and stool, vomiting is absent or late, there may be a palpable tumor
- diagnosis: X-ray of native standing (ileus image), possibly. short colonoscopy after infusion.

## 3. Ulcerative colitis

- The disease is often known from a personal history, there is also a family history of IBD (Inflammatory Bowel Disease).
- Pain occurs during exacerbation of inflammation and perforation of ulcers (with subsequent limited or diffuse peritonitis).
- Clinical picture: acute pain in the left lower abdomen with diarrhea with blood and mucus.
- *You can find more detailed information on the page Ulcerative colitis.*



X-RAY of Ileus

## 4. Diverticular disease

- Clinical picture:
  - Colical pain in the left lower abdomen is typical, caused by spasms of the muscles of the large intestine or actual obstruction, or perforation of an inflamed diverticulum with the development of peritonitis.
  - Bloody diarrhea with mucus, elevated temperature and high CRP are common. Diagnosis: colonoscopy, but only 6-8 weeks after the inflammation subsides.
- Therapy:
  - uncomplicated diverticulitis is treated with diet (residue-free diet), i.v. administration of ATB (e.g. Amoksklav i. v. + Entizol supp.);
  - complications are solved operatively (perforation of the diverticulum, ileus).

*You can find more detailed information on the page Diverticular disease.*

## 5. Other causes

- Leftsided appendicitis;
- Adnexitidis;
- Extrauterine pregnancy

## References

### Following articles

- Painful syndrome of the right lower abdomen
- Painful syndrome of the upper abdomen

### Sources

- PASTOR, Jan. *Langenbeck's medical web page* [online]. [cit. 2009]. <langenbeck.webs.com>.