

# Osteopoikilosis

**Osteopoikilosis** (*osteopoicilia*) is a very rare AD hereditary disease.

It is manifested by irregular thickenings of the bone → we find round or oval islands hyperostosis inside the cancellous bones and the metaphysis and epiphysis.

## Clinical picture

- Usually **without significant clinical manifestations**;
- the disease is mostly revealed as an **accidental X-ray finding**;
- in 10% affected subcutaneous and skin nodules (***dermatofibrosis lenticularis disseminata*** - Bloch-Sulzberg syndrome).

## X-ray image

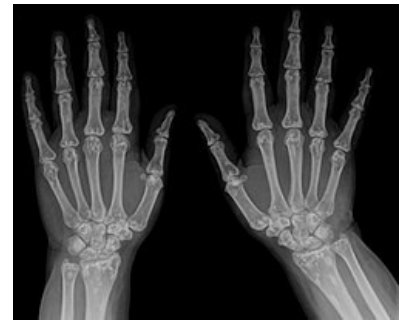- Irregularly demarcated **sclerosis** → characteristic mottled appearance of the skeleton.

## Treatment

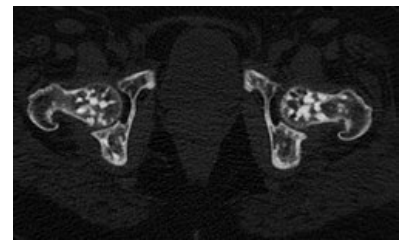
- **None** (illness without subjective difficulties);
- in adults, bone metastases must be distinguished.

## References

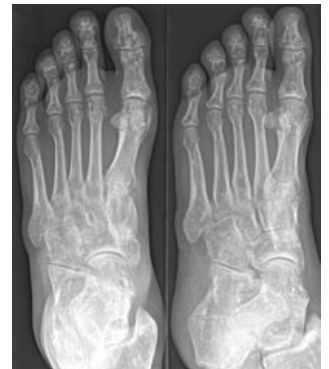DUNGL, Pavel, et al. *Ortopedie*. 1. edition. Praha : Grada Publishing, 2005. ISBN 80-247-0550-8.



Osteopoikilosis of the skeleton of the hand.



Osteopoikilie Huefte CT



Osteopoikilie Fuss - 48jm -  
Roe 2Eb - 001