

# Ossifying fibroma

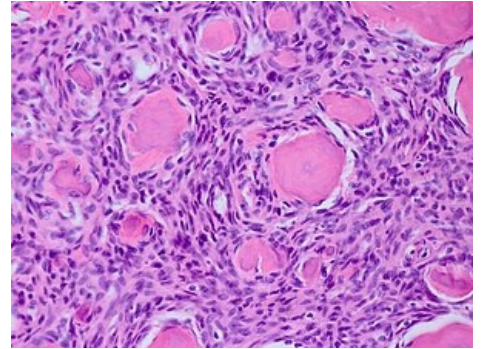
Ossifying fibroma refers to **fibro-osteoma** (fibrocementoma, osteogenic fibroma, benign osteoblastoma). It is a benign non-epithelial cancer that is difficult to distinguish from fibrous dysplasia. Fibro-osteoma, unlike dysplasia, is encapsulated.

## Occurrence

- It occurs in children and at a young age.

## Characteristics

- The mandible is most often affected.
- The jaw enlarges slowly, but does not hurt.
- The face deforms.
- Due to encapsulation, the tumor can be easily removed.
- We find calcifications of various sizes.



Ossifying fibroma, HE preparation

## Links

### Related articles

- Fibrous bone dysplasia
- Cherubism

### References

- LIŠKA, Karel. *Orofaciální patologie : Učebnice pro lékařské fakulty*. 1. vydání. Praha : Avicenum, 1983.