

Oligodendroglioma

Oligodendroglioma is a benign to semi-minimal neuroepithelial brain tumor. It represents about 4% of all brain tumors. It is located mainly in the frontal lobe. In **50-80% of cases, it manifests as epileptic seizures**. It often contains calcifications (visible on X- rays). Treatment includes surgical approaches, as radical as possible, adjuvant CHT (Procarbazine, Vincristine), and RT. Survival rate after ten years is 10-30%.

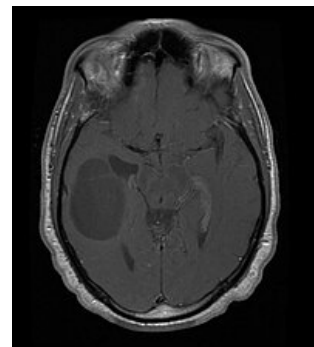
References

Source

- BENEŠ, Jiří. *Studijní materiály* [online]. ©2007. [cit. 2009]. <<http://www.jirben.wz.cz/>>.

Used literature

- ZEMAN, Miroslav, et al. *Speciální chirurgie*. 2. vydání. Praha : Galén, 2004. 575 s. ISBN 80-7262-260-9.



MRI with gadolinium contrast agent - Oligodendroglioma